

## Protective Effect of Hesperidin against Methotrexate-Induced Nephrotoxicity in Rats

Sara A. Aldossary

[saldossary@kfu.edu.sa](mailto:saldossary@kfu.edu.sa)

Pharmaceutical Sciences Department, College of Clinical Pharmacy, King Faisal University, Alahssa, Saudi Arabia

**Abstract:** The present study investigated the probable protective effect of hesperidin against kidney injury induced by methotrexate in rats. The rats received a single injection of methotrexate (20 mg/kg, i.p.). Hesperidin treatment (100 mg/kg/day, p.o.) was started 1 day before administration of methotrexate, and continued for 7 days. Methotrexate significantly increased serum creatinine, and renal malondialdehyde, nitric oxide, tumor necrosis factor- $\alpha$ , nuclear factor- $\kappa$ B p65, and caspase-3, and significantly decreased renal total antioxidant capacity in rats. Hesperidin significantly ameliorated the changes of biochemical parameters induced by methotrexate. Hesperidin also significantly reduced methotrexate-induced histopathological kidney tissue injury. In conclusion, hesperidin significantly protected against methotrexate-induced kidney injury in rats by inhibiting oxidative/nitrosative stress, inflammation, and apoptosis.

[Aldossary SA. **Protective Effect of Hesperidin against Methotrexate-Induced Nephrotoxicity in Rats.** *Life Sci J* 2022;19(12):27-30]. ISSN 1097-8135 (print); ISSN 2372-613X (online). <http://www.lifesciencesite.com>. 04.doi:[10.7537/marslsj191222.04](https://doi.org/10.7537/marslsj191222.04).

**Keywords:** Hesperidin; methotrexate; nephrotoxicity; rats

### 1. Introduction

Methotrexate (MTX), the antifolate drug, is a commonly used cancer chemotherapeutic agent. MTX is used for leukemia, lymphoma, osteosarcoma, lung, and breast cancers. Additionally, MTX is used as an immunosuppressant in rheumatoid arthritis, psoriasis, and inflammatory bowel diseases (Khan et al., 2012). Despite wide clinical uses and high efficacy, nephrotoxicity associated with high morbidity and mortality remains a major and dose-limiting problem of MTX. Acute kidney injury (AKI) and dysfunction occurs in about 2-12% of patients with hematological malignancies treated with high-dose MTX (Howard et al., 2016). Increased generation of reactive oxygen species (ROS), and reactive nitrogen species (RNS) seem to play a pivotal role in the pathogenesis of MTX nephrotoxicity (Armagan et al., 2015). Oxidative/nitrosative stress increases the production of inflammatory cytokines, as tumor necrosis factor- $\alpha$  (TNF- $\alpha$ ), via activation of nuclear factor- $\kappa$ B (NF- $\kappa$ B) pathway. Subsequent up-regulation of the apoptotic pathways finally leads to AKI and renal failure (Erboga et al., 2015). In addition, several antioxidants and anti-apoptotic agents were used successfully against AKI induced by MTX (Dabak and Kocaman, 2015; Ulusoy et al., 2016).

Hesperidin (HN) is an active flavonoid found in citrus fruits possessing antioxidant and anti-inflammatory actions (Li and Schluesener, 2017). It was reported that HN significantly protected against AKI induced by cisplatin, acrylamide, and iron in rats (Pari et al., 2014; Kumar et al., 2017; Hamdy et al., 2017). HN also significantly prevented diabetic nephropathy in rats and mice with diabetes mellitus (Iskender et al., 2017; Zhang et al., 2018). In addition, the effect of HN against MTX nephrotoxicity was not yet investigated. Therefore, the present work was done to investigate the probable protective effect of HN against MTX-induced AKI in rats.

### 2. Material and Methods

#### Drugs

HN and MTX were purchased from Sigma-Aldrich, USA. HN was prepared in 0.5% carboxymethylcellulose (CMC) solution, and MTX was dissolved in physiological saline. The doses of HN and MTX were selected based on previous investigations (Erboga ET AL., 2015; Siddiqi ET AL., 2015).

#### Animals

The Animal House, College of Medicine, King Faisal University, provided 40 male Sprague-Dawley rats, weighing 200-250 g. The rats were kept

in standard housing conditions (24°C, 45% humidity, and 12h light/dark cycle), and supplied with commercial chow and tap water *ad libitum*. The experiments were done according to the international guidelines for care and use of laboratory animals.

#### Study plan

The rats were randomly allocated into 4 equal groups ( $n = 10$ ), as follows:

- Group 1: (control) received a daily i.p. injection of physiological saline for 7 days.
- Group 2: received a single i.p. injection of MTX (20 mg/kg), and oral CMC daily for 7 days starting 1 day before MTX administration.
- Group 3: received MTX, and treated with HN (100 mg/kg/day, p.o.) for 7 days starting 1 day before MTX administration.
- Group 4: received only HN for 7 days.

#### Sampling and biochemical processes

Rats were euthanized by thiopental (70 mg/kg, i.p.) at the end of the experiments. Blood was collected via left ventricular puncture. Serum creatinine was measured by a commercial colorimetric kit (Biovision Inc., USA). The kidneys were dissected, the right kidneys were homogenized in cold potassium phosphate buffer (pH 7.4, 0.05 M), and the homogenate was centrifuged at 5000 rpm for 10 min at 4°C. The supernatant was used to assess malondialdehyde (MDA), nitric oxide (NO), and total antioxidant capacity (TAC) by colorimetric kits (Biovision Inc., USA). Tumor necrosis factor- $\alpha$  (TNF- $\alpha$ ) was also measured using an ELISA kit (R&D Systems, USA). In addition, a colorimetric kit (R&D Systems, USA) was used to determine caspase-3 activity.

A portion of the kidney homogenate was re-centrifuged at 15,000 rpm for 30 min at 4°C, and the pellet (nuclear fraction) was used to measure NF- $\kappa$ B p65 unit by an ELISA kit (Novus Biologicals, USA).

#### Histopathology processes

The left kidneys were fixed in formalin 10% solution, and embedded in paraffin wax. Sections were cut at 5  $\mu$ m, stained with hematoxylin and eosin (H&E), and examined under light microscope.

#### Statistical analysis

Data analysis (mean  $\pm$  S.E.M.) was done using GraphPad Prism Software Program, version 6.01 by applying one-way ANOVA test followed by Tukey test for *post hoc* comparisons, and significance was at  $p < 0.05$ .

### 3. Results

Administration of a single dose of MTX (20 mg/kg, i.p.) resulted in significant increase of serum creatinine as compared to the control ( $p < 0.05$ ). On the other hand, HN treatment (100 mg/kg/ day, p.o.)

for 7 days starting 1 day before MTX injection, significantly decreased serum creatinine in rats received MTX ( $p < 0.05$ ) (Figure 1).

In addition, MTX administration significantly increased renal MDA, NO, and significantly decreased kidney TAC in rats as compared to the control ( $p < 0.05$ ). However, HN treatment significantly decreased renal MDA and NO, and significantly increased TAC in kidneys of rats challenged with MTX ( $p < 0.05$ ) (Figure 2).

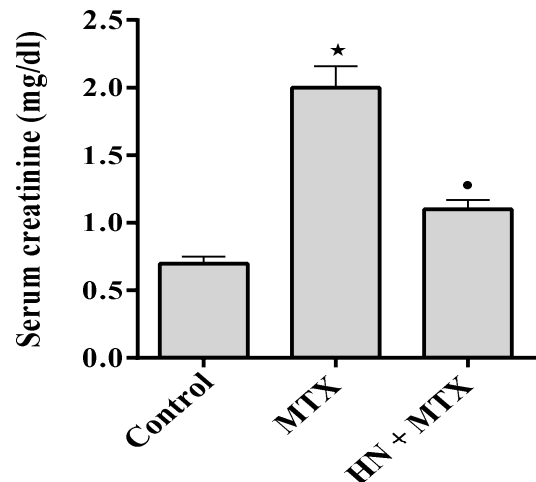


Figure 1. Effect of hesperidin (HN) on serum creatinine in rats received methotrexate (MTX). Results are mean  $\pm$  S.E.M., \* $p < 0.05$  vs. control, \* $p < 0.05$  vs. MTX.

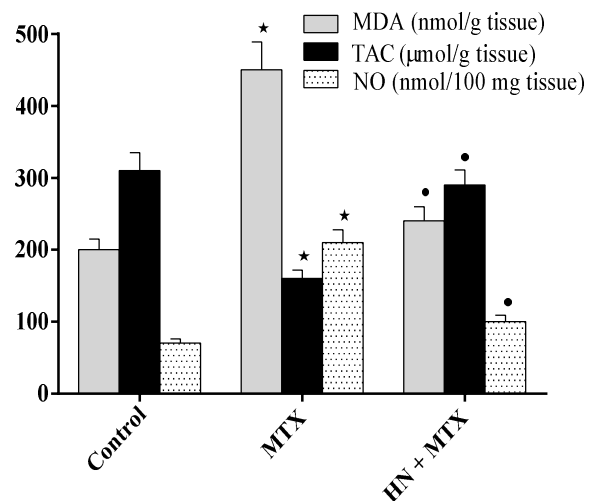


Figure 2. Effects of hesperidin (HN) on kidney malondialdehyde (MDA), nitric oxide, and total antioxidant capacity (TAC) in rats received methotrexate (MTX). Results are mean  $\pm$  S.E.M., \* $p < 0.05$  vs. control, \* $p < 0.05$  vs. MTX.

Moreover, MTX significantly increased TNF- $\alpha$  and NF- $\kappa$ B p65 in rat kidneys as compared to the control ( $p < 0.05$ ). Contrarily, HN treatment significantly decreased TNF- $\alpha$  and NF- $\kappa$ B p65 in kidneys of rats challenged with MTX ( $p < 0.05$ ) (Figure 3). Additionally, HN significantly prevented the increase of and caspase-3 induced by MTX in rat kidneys ( $p < 0.05$ ) (Figure 4).

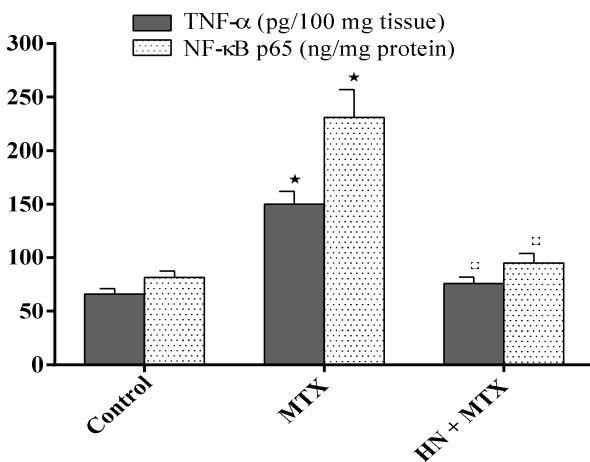


Figure 3. Effects of hesperidin (HN) on kidney nuclear factor- $\kappa$ B p65 (NF- $\kappa$ B p65) and tumor necrosis factor- $\alpha$  (TNF- $\alpha$ ) in rats received methotrexate (MTX). Results are mean  $\pm$  S.E.M., \* $p < 0.05$  vs. control,  $^{\dagger}p < 0.05$  vs. MTX.

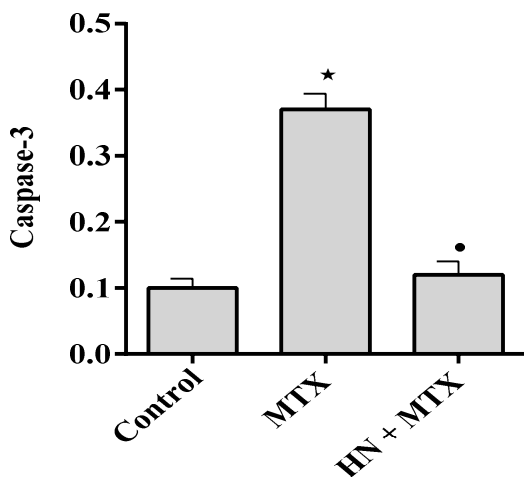


Figure 4. Effects of hesperidin (HN) on caspase-3 in kidneys of rats received methotrexate (MTX). Results are mean  $\pm$  S.E.M., \* $p < 0.05$  vs. control,  $^{\dagger}p < 0.05$  vs. MTX.

Histopathological examination showed widespread renal tubular necrosis, degeneration and desquamation of tubular epithelium, vacuolization, interstitial edema, and leukocytic infiltration in rat kidneys challenged with MTX. Treatment with HN markedly minimized renal injury induced by MTX (Figure 5).

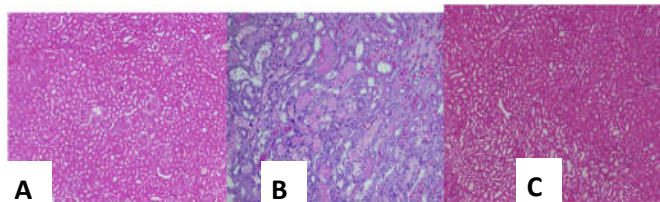


Figure 5. H&E (200 $\times$ ) of rat kidneys from: (A) control showing normal renal histology; (B) methotrexate (MTX) group showing marked distortion of kidney architecture, widespread necrosis of renal tubules, tubular dilatation, epithelial desquamation, vacuolization, and coagulative necrosis; (C) hesperidin (HN) + MTX showing that normal kidney architecture is preserved.

The results obtained with the group of rats received HN only were comparable to the corresponding values of the control group without significant differences (results not shown).

#### 4. Discussions

The molecular mechanisms underlying nephrotoxicity induced by MTX are multifactorial. Growing evidence indicates the major role of oxidative stress, increased ROS generation, depletion of endogenous antioxidants, and lipid peroxidation of biological membranes with increased MDA production in the pathogenesis of AKI induced by MTX (Abd El-Twab et al., 2016). Production of ROS activates the inflammatory cascades, particularly TNF- $\alpha$ , NF- $\kappa$ B, and NO pathways. The ROS and TNF- $\alpha$  surge boost nuclear translocation of NF- $\kappa$ B p65, the main unit of cytoplasmic NF- $\kappa$ B sequestration, which augments gene transcription of TNF- $\alpha$ . Therefore, the inflammatory responses, RNS yield, and nitrosative stress of cellular macromolecules are reinforced (Abdel-Raheem and Khedr, 2014). This is in accordance with the current investigation, in which MTX up-regulated the oxidative, nitrative, and inflammatory markers in rat kidneys. In addition, the present study illustrated that HN significantly impeded AKI induced by MTX as demonstrated by decreased lipid peroxidation, preservation of antioxidant defenses, inhibition of inflammatory responses, and suppression of NF- $\kappa$ B pathway. Similarly, earlier reports related the nephroprotective effect of HN to the inhibition of

oxidative/nitrative stress, and inflammation (Siddiqi et al., 2015; Turk et al., 2018).

In the same line, previous investigations revealed that apoptotic pathways are involved in AKI induced by MTX (Hafez et al., 2015; Gad et al., 2017). The present study also disclosed that HN significantly inhibited the activation of caspase-3, the main executioner of apoptotic cell death (Subasic et al., 2016), through its antioxidant and anti-inflammatory effects.

In agreement with the present work, past studies showed that MTX caused significant histopathological kidney tissue injuries (Hafez et al., 2015; Asci et al., 2017). The present study also denoted that kidney architecture was significantly kept intact in MTX-challenged rats and treated with HN.

From the current results, it was concluded that HN significantly protected against MTX-induced AKI in rats by inhibiting oxidative and nitrative stresses, inflammation, and apoptosis.

#### Corresponding Author:

Dr. Sara A. Aldossary  
Department of Pharmaceutical Sciences  
College of Clinical Pharmacy, King Faisal University  
Alahssa, Saudi Arabia  
E-mail: [saldossary@kfu.edu.sa](mailto:saldossary@kfu.edu.sa)

#### References

- [1]. Khan ZA, Tripathi R, Mishra B. Methotrexate: a detailed review on drug delivery and clinical aspects. *Expert Opin Drug Deliv* 2012;9:151-69.
- [2]. Howard SC, McCormick J, Pui CH et al. Preventing and managing toxicities of high-dose methotrexate. *Oncologist* 2016;21:1471-82.
- [3]. Armagan I, Bayram D, Candan IA, et al. Effects of pentoxifylline and alpha lipoic acid on methotrexate-induced damage in liver and kidney of rats. *Environ Toxicol Pharmacol* 2015;39:1122-31.
- [4]. Erboga M, Aktas C, Erboga ZF, et al. Quercetin ameliorates methotrexate-induced renal damage, apoptosis and oxidative stress in rats. *Ren Fail* 2015;37:1492-7.
- [5]. Dabak DO and Kocaman N. Effects of silymarin on methotrexate-induced nephrotoxicity in rats. *Ren Fail* 2015;37:734-9.
- [6]. Ulusoy HB, Öztürk İ, Sönmez MF. Protective effect of propolis on methotrexate-induced kidney injury in the rat. *Ren Fail* 2016;38:744-50.
- [7]. Li C, Schluesener H. Health-promoting effects of the citrus flavanone hesperidin. *Crit Rev Food Sci Nutr*. 2017;57:613-31.
- [8]. Pari L, Karthikeyan A, Karthika P, et al. Protective effects of hesperidin on oxidative stress, dyslipidaemia and histological changes in iron-induced hepatic and renal toxicity in rats. *Toxicol Rep* 2014;2:46-55.
- [9]. Hamdy SM, Shabaan AM, Abdel Latif AKM, et al. Protective effect of hesperidin and tiger nut against acrylamide toxicity in female rats. *Exp Toxicol Pathol* 2017;69:580-8.
- [10]. Kumar M, Dahiya V, Kasala ER, et al. The renoprotective activity of hesperetin in cisplatin induced nephrotoxicity in rats: Molecular and biochemical evidence. *Biomed Pharmacother*. 2017; 89: 1207-1215.
- [11]. Iskender H, Dokumacioglu E, Sen TM, et al. The effect of hesperidin and quercetin on oxidative stress, NF- $\kappa$ B and SIRT1 levels in a STZ-induced experimental diabetes model. *Biomed Pharmacother* 2017;90:500-8.
- [12]. Zhang Y, Wang B, Guo F, et al. Involvement of the TGF $\beta$ 1- ILK-Akt signaling pathway in the effects of hesperidin in type 2 diabetic nephropathy. *Biomed Pharmacother* 2018;105:766-72.
- [13]. Siddiqi A, Nafees S, Rashid S, et al. Hesperidin ameliorates trichloroethylene-induced nephrotoxicity by abrogation of oxidative stress and apoptosis in wistar rats. *Mol Cell Biochem* 2015;406:9-20.
- [14]. Abd El-Twab SM, Hozayen WG, Hussein OE, et al. 18 $\beta$ -Glycyrrhetic acid protects against methotrexate-induced kidney injury by up-regulating the Nrf2/ARE/HO-1 pathway and endogenous antioxidants. *Ren Fail* 2016;38:1516-27.
- [15]. Abdel-Raheem IT and Khedr NF. Renoprotective effects of montelukast, a cysteinyl leukotriene receptor antagonist, against methotrexate-induced kidney damage in rats. *Naunyn Schmiedebergs Arch Pharmacol* 2014;387:341-53.
- [16]. Turk E, Kandemir FM, Yildirim S, et al. Protective effect of hesperidin on sodium arsenite-induced nephrotoxicity and hepatotoxicity in rats. *Biol Trace Elem Res* 2018; doi: 10.1007/s12011-018-1443-6.
- [17]. Hafez HM, Ibrahim MA, Ibrahim SA, et al. Potential protective effect of etanercept and aminoguanidine in methotrexate-induced hepatotoxicity and nephrotoxicity in rats. *Eur J Pharmacol* 2015;768:1-12.

- [18]. Gad AM, Hassan WA, Fikry EM. Significant curative functions of the mesenchymal stem cells on methotrexate-induced kidney and liver injuries in rats. *J Biochem Mol Toxicol* 2017;31:e21919.
- [19]. Subasic D, Stoeger T, Eisenring S, et al. Post-transcriptional control of executioner caspases by RNA-binding proteins. *Genes Dev* 2016;30:2213-25.
- [20]. Asci H, Ozmen O, Ellidag HY, et al. The impact of gallic acid on the methotrexate-induced kidney damage in rats. *J Food Drug Anal* 2017;25:890-7.

12/2/2022