



## Review on nematode disease of camel and its diagnoses approach in Ethiopia

Abebe Mequanent

University of Gondar College of Veterinary Medicine and Animal Science, Department of Veterinary  
Clinical Medicine, Gondar, Ethiopia, P.o. Box: 196

E-mail: [abebemequanent@gmail.com](mailto:abebemequanent@gmail.com)

**Summary:-** Camels like other domestic animals suffer from heavy burdens of helminthes. When camels are kept in higher rainfall areas or intensively stabled, parasitic gastroenteritis may result. Nematodes are practically specific to the dromedary. Nematode disease of camel is mostly caused by *Haemonchus longispes*, *Nematodirus Mauritanicus*, *Nematodirus dromedarii* and has more economic significance in camels. However, most of camel nematodes are also common to Sheep and Goats, like *Trichostrongylus prololurus*, *Tichostrongylus vitrinus*, *Ostertagia mongolica*, *Nematodirus spathiger*, *Oesophagostomum venulosum*. *Haemonchus longistipes* is specific to camels and mostly found in: Africa Asia. Mostly its transmission of the disease occurs by direct contact or via fomites, such as blankets and baggage etc. The Diagnosis of the disease is made on the basis of clinical symptoms and by finding the different developmental stages ova or larvae nematodes. Anthelmintics used in cattle and sheep for the treatment of digestive tract helminthoses can also be used in camels.

[Abebe, M.A. **Review on nematode disease of camel and its diagnoses approach in Ethiopia.** *Life Sci J* 2022;19(11):54-56]. ISSN 1097-8135(print);ISSN2372-613X (online). <http://www.lifesciencesite.com>. 07.doi:[10.7537/marslsj191122.07](https://doi.org/10.7537/marslsj191122.07).

**Key words:** - *Camel, disease and nematode*

### 1. INTRODUCTION

The camel is the least likely of all domestic livestock to suffer from heavy burdens of helminthes. The arid climate and dung beetle activity in arid Central Australia are not conducive to heavy worm burdens, although low grades of nematode infestation are common. When camels are kept in higher rainfall areas or intensively stabled, parasitic gastroenteritis may result.

Nematodes some appear to be practically specific to the dromedary. Camel specific nematodes are included; *Haemonchus longispes*, *Nematodirus Mauritanicus*, *Nematodirus dromedarii* but most of camel Nematodes are also common to Sheep and Goats, like *Trichostrongylus prololurus*, *Tichostrongylus vitrinus*, *Ostertagia mongolica*, *Nematodirus spathiger*, *Oesophagostomum venulosum*.

#### 1.1. Definition

Nematode disease of camel is mostly caused by *Haemonchus longispes*, *Nematodirus Mauritanicus*, *Nematodirus dromedarii* and has more economic significance in camels.

#### 1.2. Etiology

Among the **nematodes**, some appear to be practically specific to the dromedary (*Haemonchus longistipes*, *Nematodirus mauritanicus*, *Nematodirus dromedarii*) or for the bactrian camel (*Chabertia reshati*). Among species of the genus *Trichostrongylus*, *T.*

*colubriformis*, *T. probolurus* and *T. vitrinus* are the species found most often in camels. *T. colubriformis* essentially parasitizes the duodenum, but has been found occasionally in the abomasum. The other two species are found in the small intestine. *T. calcaratus* and *T. affinis* are mainly parasites of rodents which have been found occasionally in Camelidae. *Cooperia oncophora* and *C. pectinata* occur mainly in the small intestine and exceptionally in the abomasum of ruminants. They have an extensive geographical distribution and are found occasionally in camels.

Infection by larval stages usually takes place during the rainy season, when grass is the main feed instead of shrubs and trees. Massive infestations and combinations of parasites (combination of species of nematodes, or of nematodes and cestodes) occur frequently and are accompanied by high morbidity.

#### 1.3. Epidemiology

*Haemonchus longistipes* is specific to camels and is found in: Africa: like East (116, 146, 193, 194, 127, 170, 34, 161, 13, 167), North (according to 191), West (133), Centre (88, 89, 91, 92, 60, 61, 161, 163, 201, 196) and in Asia: like:- Arab Peninsula (8, 72, 100, 71), India and Pakistan (84, 39, 115, 29, 30, 32, 157, 142). Camel *ostrongylus mentulatus* the geographical distribution of this nematode coincides with that of camels.

However, in the African continent it is common only in the North (58), and is quite rare elsewhere.

*Nematodirus spathiger*, *N. mauritanicus*, *N. abnormalis*, *N. dromedarii* and *N. helvetianus* have been identified in the small intestine of camels wherever they are kept.

#### 1.4. Transmission

Transmission of the disease occurs by direct contact or via fomites, such as blankets and baggage etc. Due to severe itching infected camels rub against their calves, other animal or trees and spread the disease. Affected camels become restless due to intense pruritis and they bite, scratch and rub the affected areas which may lead to formation of large wound with maggot infestation and secondary bacterial infections.

#### 1.5. Diagnosis

Diagnosis of the disease is made on the basis of clinical symptoms and by finding the different developmental stages ova or larvae nematodes. Diagnosis by examining faeces provides useful information, despite the limitations referred to below. An egg count above 600 eggs per gram of faeces indicates a number of helminths sufficient to cause physiological disorders. Considered that animals are severely affected if the egg count is greater than 1000. However, many factors are responsible for producing variation in the worm egg count, regardless of the number of helminthes present, including the phenomenon of hypobiosis and also nutritional and immunological factors, like:- In the special case of oesophagostomiasis, which is a disease caused mainly by larval stages; there may be no eggs at all in the faeces and in the living animal, diagnosis can be performed only in the case of dictyocaulosis, from the symptoms described above and the presence of larvae in the faeces.

#### 1.6. Clinical and pathological features

These includes:- Under natural conditions camels are practically never infested with just a single species of gastro-intestinal helminthes, for multiple parasitisms is the rule. With the exception of acute haemonchosis, it is practically impossible to distinguish the diseases produced by different helminthes and hence the clinical picture of these helminthosis is a combination of symptoms induced by various species. For these reasons we shall describe separately the clinical and pathological features of haemonchosis and those caused by other helminths.

#### 1.7. Clinical sign

It is generally agreed that this disease is the most severe gastro-intestinal helminthosis of camels. The clinical picture is one of anaemia associated with general illness. Symptoms develop only when the

infestation is severe (more than 150 nematodes). In general it occurs most often in young animals, and is manifested by: 1) General weakness and, in lactating females, a fall in milk yield 2) Anemia recognised by pallor of the visible mucosa 3) Edema of the hollow above the eye, the sides of the sternal cushion (resulting in a characteristic and well-recognised swelling), and sometimes between the jaws 4) Progressive wasting 5) Sometimes depraved appetite, with ingestion of considerable amounts of sand 6) Abortion (rare) and death, which may occur after several weeks of illness.

#### 1.8. Histopathology

Histologically, there were inflammatory reactions mainly of lymphocytes and eosinophils and hyperemia in the abomasal mucosa with hyperplasia of abomasal glands of infected animals (Fig. 1). Histopathological study revealed loss of intestinal villi with eosinophilic infiltration. There is thickened mucosa with infiltration of inflammatory cells in duodenum. There is heavy infiltration of inflammatory cells in the mucosa and sub-mucosa (Fig. 2). There was sloughing of epithelium and hyperplasia of duodenal glands (Fig. 3 and 4).

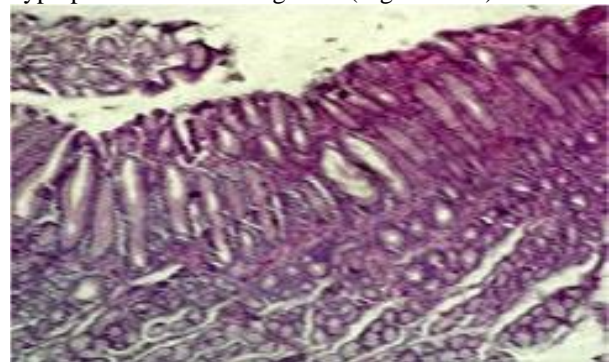


Fig1: Hyperplasia of abomasal glands (H&E, 100 X)

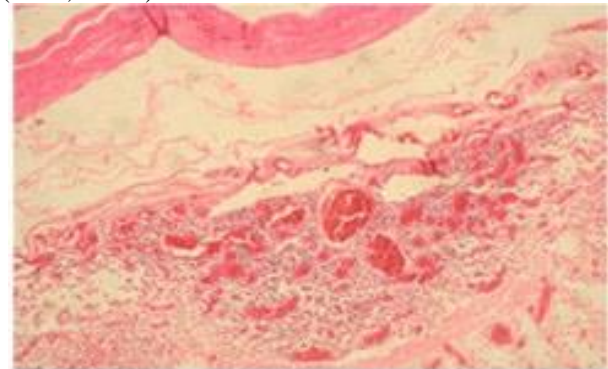


Fig 2: Sub-mucosal infiltration in duodenum (H&E, 100 X)

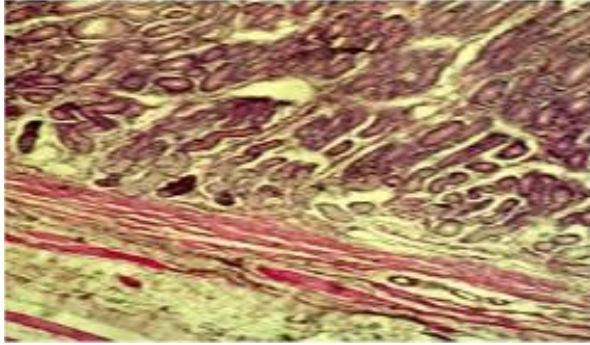


Fig 3: Hyperplasia of duodenal glands (H&E,100X)

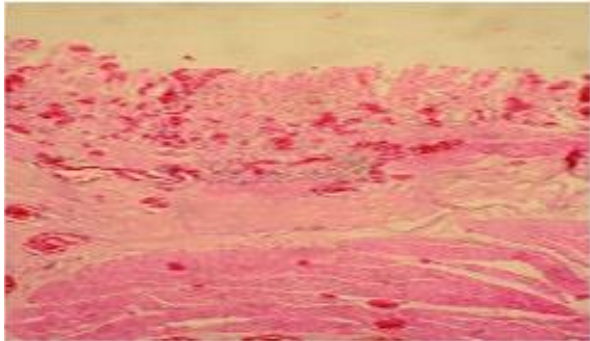


Fig 4: Sloughing of epithelium in duodenum (H&E, 100 X).

### 1.9. Treatment

Most of the anthelmintics used in cattle and sheep for the treatment of digestive tract helminthoses can also be used in camels.

### 1.10. Prophylaxis

As in the case of gastro-intestinal helminthoses of other animal species (particularly ruminants), prevention of those of camels can be successful only when epidemiological data are taken into account. In general terms there are two possibilities for action: 1) Action against free-living stages of the parasitic nematodes, which is restricted to keeping the ground around watering points as dry as possible and action against the parasites within the host recommends antihelmintic treatment during the dry season in order to take advantage of its sterilizing effect in reducing the contamination of grazing land, which takes place during the rainy season.

### Acknowledgements:

Foundation item: The National Project of Ethiopia Authors is grateful to the Department of veterinary clinical medicine, University of Ethiopia for financial support to carry out this work.

### Corresponding Author:

Dr. Abebe Mequanent, Department of veterinary clinical medicine, Tewodros Campus,

Gondar University of Ethiopia. Telephone: 091-822-0138, E-mail: [abebemequanent@gmail.com](mailto:abebemequanent@gmail.com)

## 2. References

- [1]. Animal Health Australia (2002). The history of Bluetongue, Akabane and Ephemeral Fever Virus and their vectors in Australia 1975 –1999. ISBN 1 87671421 2.
- [2]. Dakkak.A and Ouhelli., H (1987). Helminths and helminthoses of the dromedary. A review of the literature. *Rev. sci. tech. Off. int. Epiz.*, 6 (1), 447-461.
- [3]. Pantuliano S, Wekesa M (2008). Improving Drought Response in Pastoral Areas of Ethiopia" Overseas Development Institute. Humanitarian Policy Group Overseas Development Institute, London, pp. 1-42.
- [4]. Tefera, B., 2009. Seroprevalence of camel brucellosis in pastoral areas of Ethiopia, DVM thesis, pp. 12-20.

11/20/2022

7/11/2022