



The effect of Intravitreal Injection of Bevacizumab (Avastin) on Diabetic Macular Edema

Naser Samadi Aidenloo, Qader Motarjemizadeh

Department of ophthalmology, Urmia University of Medical Sciences, Urmia, Iran

Dr.mahyar@yahoo.com

Abstract: This study was carried out to specify the effects of intravitreal injection of bevacizumab (Avastin) on diabetic macular edema, (DME) as the primary treatment of diabetic macular edema. In a quasi-experimental study, thirty eyes from thirty diabetic patients diagnosed with CSME were exposed to intravitreal bevacizumab in accordance with ETDRS standards. All patients were monitored for three months. In other words, they were evaluated within three stages: a day before the injection, 1.5 and 3 months after the shot. The examinations surveyed a review of the vision, intraocular pressure and the central macular thickness with OCT. The mean visual acuity of the patients was 0.307 ± 0.1856 before the shot which improved to 0.577 ± 0.2431 after a month and 0.417 ± 0.2102 after three months. Having injected for three months, the average level of vision reduced remarkably in terms of statistics compared to its noticeable raise from the baseline. Before the shot, the macular central thickness was 340.6 ± 85.1099 whereas it reduced to 245.6 ± 64.153 after 1.5 month off injection and 295.63 ± 68.507 after 3 months. Macular central thickness grade increased remarkably after 3 months off the shot comparing to 1.5 month after the shot. But, it reduced noticeably compared to the baseline. This study suggests that intravitreal injection of bevacizumab significantly improved vision and decreased central macular thickness within 3 months after injection, and this treatment does not lead to any problems in the short term.

[Naser Samadi Aidenloo, Qader Motarjemizadeh. **The effect of Intravitreal Injection of Bevacizumab (Avastin) on Diabetic Macular Edema.** *Life Sci J* 2021;18(12):43-48]. ISSN 1097-8135 (print); ISSN 2372-613X (online). 6. doi:[10.7537/marslsj181221.06](https://doi.org/10.7537/marslsj181221.06).<http://www.lifesciencesite.com>.

Keywords: diabetic macular edema, intravitreal injection, bevacizumab (Avastin).

1. Introduction:

Diabetic retinopathy is a widespread eye complication among the diabetics and the most common cause of sightlessness during working ages. Nowadays, it is also counted for as a major economic problem (1). Macular edema's widespread value is nearly 10% and as a non-proliferation retinopathy is the most common answer for vision loss in this population (2 and 3). This failure comes from the increase of vascular permeability which in turn results in the leakage of liquids and plasma components such as lipoproteins into retina, causing its thickness subsequently (4). Over the past thirty years, macular edema treatment has seen noticeable progress. Although laser therapy for macular edema decreases moderate vision loss by 50%, it creates 3_14% possibility for vision development. Macular distributed edema, macular ischemia, cystic degeneration and hard exudates in fovea don't have fine prognosis with the application of laser therapy though. Also, despite photo coagulation addresses those patients who have progressed blindness. This condition led to other treatments like vitrectomy or drug treatments such as steroids, anti-VEGF, and protein Kinase C inhibitors to be considered as an intravitreal injection (6 and 5).

Inducing angiogenesis factor, VEGF is an endothelial-specific mitogen that is involved in the

formation of diabetic macular edema. Studies have suggested that VEGF is the most significant mediator on the raise of vascular permeability. Bevacizumab is a human monoclonal antibody which inhibits all active isoforms of VEGF (7 and 4). These days, the intravitreal injection, 1.25 mg dose, is widely employed in the treatment of DME, though still not received the seal of approval from FDA for intravitreal injection. The research findings of Diabetic Retinopathy Clinical Research Network (DRCR net) on the impacts of intravitreal injection of bevacizumab with either 1.25 mg or 2.5 mg dose in the treatment of diabetic macular edema suggests that this drug bears no side effects such as inflammation, the increased pressure intraocular severe loss of vision, endophthalmitis with no systemic side effects (9 and 8). Kumar and Sinha (10) represented that intravitreal injection of bevacizumab decreased macular thickness dramatically and improved visual acuity over three months. Moreover, Seo and Park (2009) proved that intravitreal injection of bevacizumab led to a significant improvement in BCVA and retina thickness decreased during the first week and the first week and this effect was sustained for three months.

According to the aforementioned subjects, it is highly significant to treat diabetic macular edema in prevention of its influences and bears no effects. On the other hand, although it has not yet

FDA approved, it has been the subject of limited researches in Iran. Therefore, this study aimed to analyze the impact of intravitreal injection of bevacizumab on macular edema in diabetic patients.

2. Material and methods:

This is a quasi- experimental intervention experiment carried out on patients diagnosed as macular edema at Imam Khomeini hospital in Urmia city during three months' time. Thirty eyes of diabetic patients diagnosed with CSME according to ETDRS standards were enrolled as they all had certain characteristics. The mean age of patients was 58.3 ± 5.937 including 13 female (43.3%) and 17 male (56.7%) [figure 1]. They

were all selected non-randomly upon criteria like: the existence of CSME in Optical Coherence Tomography (OCT), the presence of diabetic retinopathy stage in Non-Proliferative Diabetic Retinopathy (NPDR), $20/200 \leq BCVA \leq 20/30$. Extraneous variables include: one eye disease, other causing factors of macular edema such as uveitis and obstruction of retinal vessels, the membranes on the retina, fibrovascular proliferation which has caused the detachment of macular, media noticeable obscurity like cataract or vitreous hemorrhage, glaucoma record or IOP higher than 21 mm mercury, surgery record, cerebrovascular accident (CVA) record, eye infection, myocardial infarction (MI) record and all treatments' reception for macular edema.

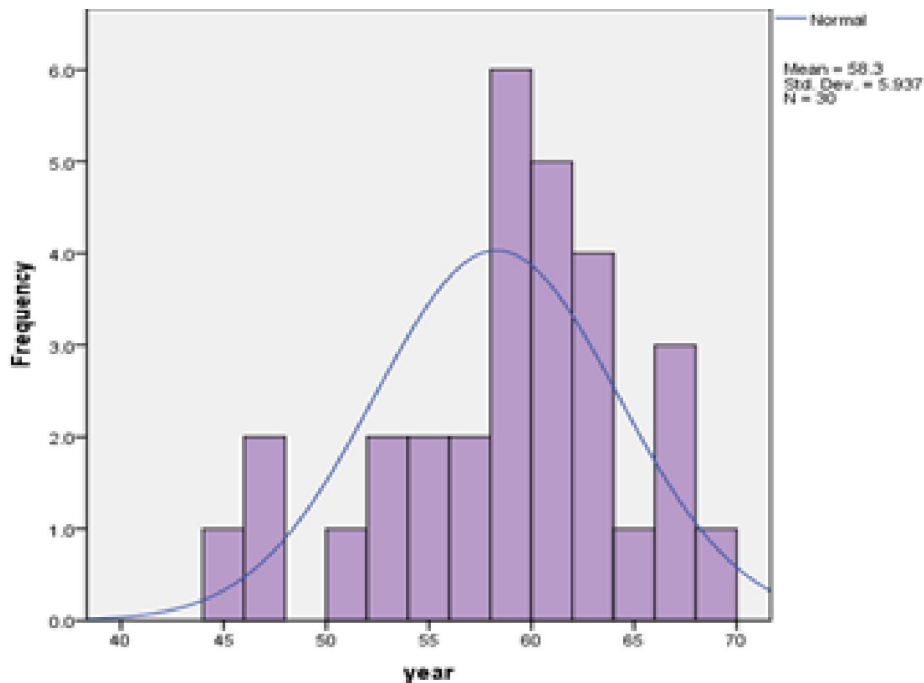


Figure1 : age distribution for the population under study

Injection technique and follow-up care:

Injection was carried out under sterile conditions using local anesthesia and Incisional Asplvm . Unilateral injection volume of 0.05 ml containing 1.25 mg of bevacizumab applied with a 30 -gauge needle from the distance of 3.75 from the limbus eye into phakic eyes or from 3.25 mm into pseudo phakic or aphakic. Then, the needle was withdrawn carefully with a sterile applicator to prevent reflux. After the injection, IOP was measured with a Schiottz tonometer and antibiotic eye drops, ciplex, the rate of four drops a day for 3 consecutive days was administered. patients' follow-up operations contain initial examinations such as visual acuity , IOP, slit lamp examination and central macular thickness measurements with OCT. Patients were evaluated within three stages: the day before injection , 1.5 months and 3 months after injection. Examination at each visit included BCVA, IOP, OCT and slit lamp examination.

Data analysis:

SPSS software was used to analyze the findings. Central macular thickness and the visual acuity to the baseline, one day before injection, 1.5 and 3 months after injection by t- test ($p \leq 0.0001$) were tested. The descriptive statistics (mean, standard deviation, and percentage) were used for the variables.

3. Results:

This study's findings show that the individual and macular's central thickness in diabetic patients have been influential meaningfully under bevacizumab's use (figures 2,3,4) and there is no mutual relevance between patients' age and sex with the side effects of drug use. Also, there were no side effects such as increased IOP, uveities, endophthalmitis during follow-up period among patients. There was a sharp raise in BCVA during 1.5 and 3 months after the shot. The patients' mean visual acuity was 0.307 ± 0.1856 before the injection. This changed into 0.577 ± 0.2431 and 0.417 ± 0.2102 after one and a half and three months off the shot respectively. The mean visual acuity saw a sharp raise after a one and a half months off the shot compared to pre-injection period ($p \leq 0.0001$ and $t = 10.43$). the mean visual acuity within three months off the shot decreased remarkably in terms of statistics comparing to the acuity for one and a half off the shot ($p \leq 0.0001$ and $t = -9.798$) but it was highly increased in comparison with pre-injection period ($p \leq 0.0001$, $t = 6.056$) within a month after the shot, two patients (% 6.66) and 25 patients (%83.33) had seen an improvement in their vision for 1 & ≥ 2 line (s) respectively. There was no improvement for three patients. Having done the injection for three months, 13 subjects (% 43.33) and 9 subjects (% 30) developed visual acuity for 1 & ≥ 2 line(s) respectively compared to pre-injection period. There was no change among 7(%23.33) subjects. The subjects' macular central thickness was 340.6 ± 85.1099 on average before the shot and turned into 245.6 ± 68.507 after 1.5 and 3 months off the shot respectively. Macular's central thickness reduced noticeably 1.5 month following intravitreal bevacizumab injection comparing to pre-injection period ($p \leq 0.0001$ & $t = -16.232$). this value increased dramatically in terms of statistics considering three months to one and a half months off the shot ($p \leq 0.0001$ & $t = 17.427$) but its low grade to pre-injection period was still statistically meaningful ($p \leq 0.0001$ & $t = -9.187$).

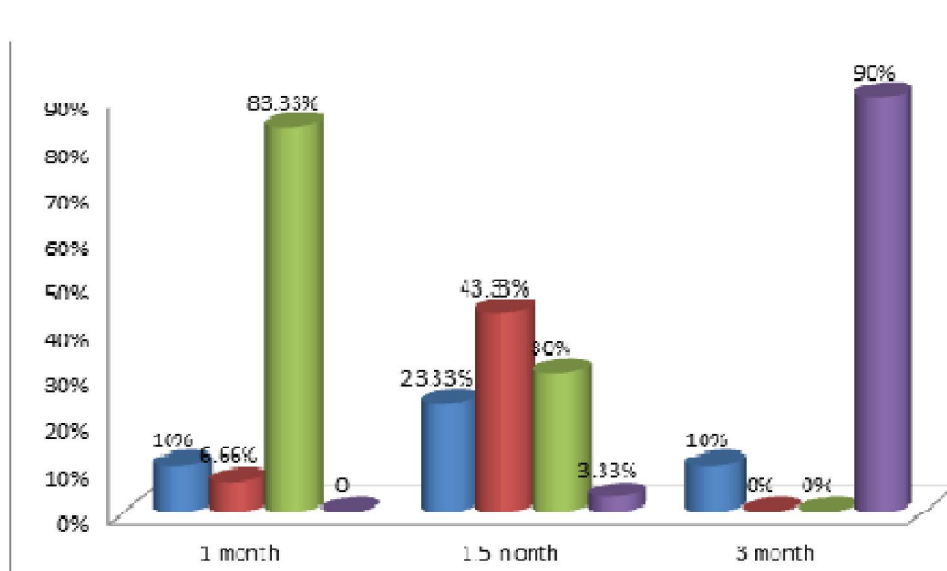


Figure2: the improvement of visual value after intravitreal injection of bevacizumab

4. Discussion:

Considering the key role of VEGF in the pathophysiology of diabetic retinopathy, inhibition of this factor can be considered as a therapeutic approach. Bevacizumab is a real VEGF blocker and may disrupt its normal physiological functions, which can be considered as a disadvantage of this drug (11). There are however some advantages as well to the use of this drug: recent public attention to this drug, availability and affordable prices, which proves the use of bevacizumab in this clinical trial. Park & Seo (4) analyzed the impact of intravitreal injection bevacizumab on visual function and retinal thickness among diabetic patients diagnosed with macular edema in a retrospective study. In the current study, some of the subjects were previously exposed

to laser therapy, intravitreal injection of triamcinolone or vitrectomy but the had not worked. Intravitreal injection of bevacizumab improved vision remarkably and decreased thickness within a week and this impact lasted for three months. Response to the treatment was irrelevant of patients' age, laser therapy record, intravitreal triamcinolone injection record. However, there was a better response on the part of those not been exposed to vitrectomy formerly. Forte et. al. (12) put under bevacizumab injections within two rounds with a month interval, 37 eyes suffering from macular edema resulting from choroid neovascularization secondary to degeneration relating to age related macular, retinal proliferation and the occlusion of branch and central retina vein. The patients' vision improved remarkably comparing basic state with the 30th and 60th days. Retina's thickness improved as well after passing two months of the shot. But, after the first month, vision decreased and retina's thickness increased. From the limitations of the current study, one can refer to the existence of three groups of macular edema diagnosed with different reasons.

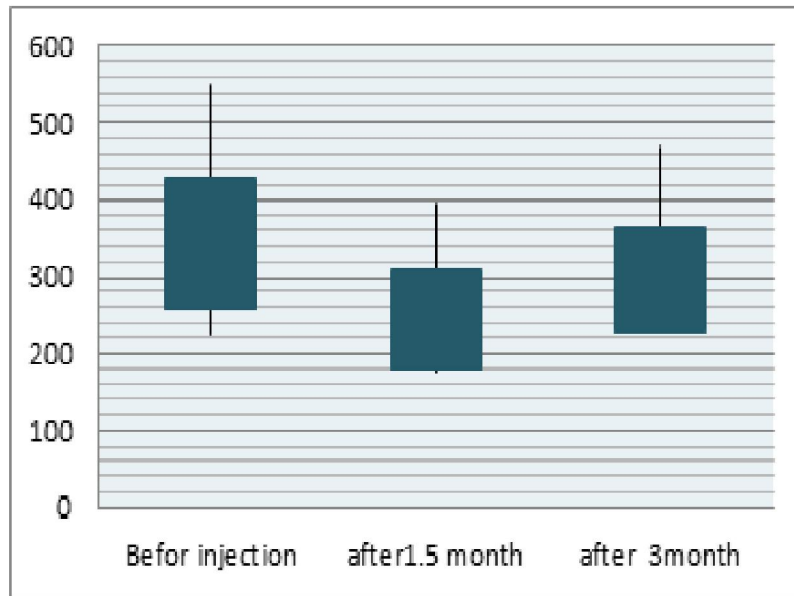


Figure 3: the diagram for the comparison of the mean of macular's central thickness before the injection and 1.5 and 3 months after the injection

In Kumar and Sinha's study (10), in India, intravitreal injection of bevacizumab applied two times with six weeks interval to twenty eyes diagnosed with macular distributed edema. All subjects of the study had previously been treated with photocoagulation. Some of them were also diagnosed with diabetic proliferated retinopathy. Although patients' vision had decreased within six months off the second shot compared to three and six months off the second shot. Macular's central thickness increased within six months off the shot to three months. However, it decreased comparing basic state with three and six months off the shot. In the current study, all subjects were at the stage of diabetic non-proliferated retinopathy whereas non had been exposed to photocoagulation (10), Intravitreal injection of triamcinolone or other treatments. In the study, there was only one injection and no relevance was observed between age and the value of response to treatment. Intravitreal injection of bevacizumab remarkably decreased macular's central thickness within 1.5 months off the shot though the thickness increased after three months. Yet, it was less than initial thickness value. Having passed 1.5 months passed the injection, the subjects' vision improved noticeably, which saw a fall over three months off the injection though there was still remarkable improvement to pre-injection period. These results can be representative of restricted impact of bevacizumab on UEGF operation suppression. Overall, according to what

has been discussed to this point, bevacizumab single shot as first line therapy for at least three months can result in patients' improvement vision.

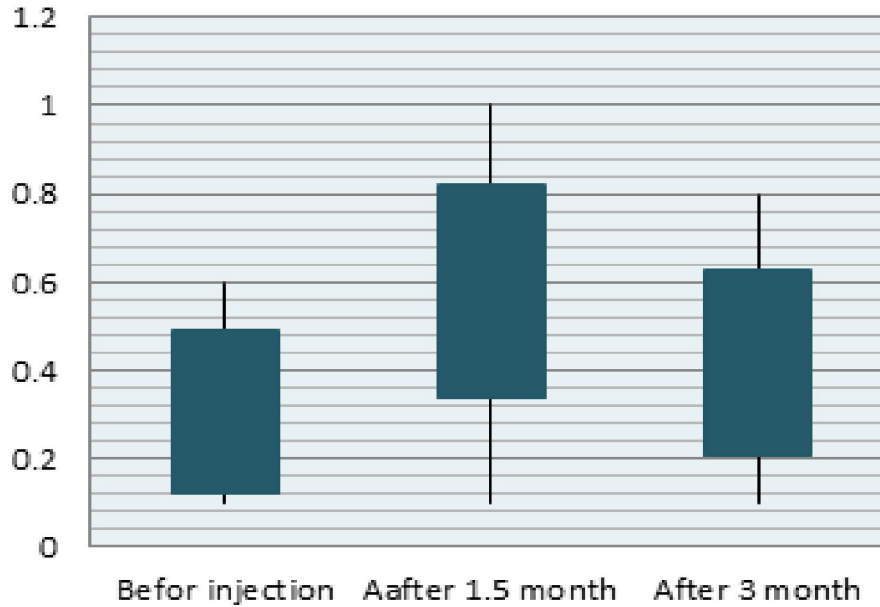


Figure 4: the diagram for the comparison of the mean of visionbefor injection and after1.5 and 3 month of injection

In the studies addressed, bevacizumab was largely employed only after other treatments non-functionality. It seems like testing bevacizumab's impact alone or with other treatments would be efficient. Thus, it is suggested that further studies be carried out to evaluate the impact of intravitreal injection of bevacizumab on diabetic macular edema patients.

Corresponding Author:

Dr. Qader Motarjemizadeh Department of ophthalmology, Urmia University of Medical Sciences, Urmia, Iran
E-mail: Dr.mahyar@yahoo.com

References:

- 1- Haritoglou C., Kook D., Neubauer A., Wolf A., Priglinger S., Strauss R et al. Intravitreal bevacizumab (avastin) therapy for persistent diffuse diabetic macular edema, *Retina*, 2006, 26.
- 2- Klein R, Klein BE, Moss SE. Visual impairment in diabetes. *Ophthalmology* 1984;91:1-9
- 3- Michaelides M., Fraser-bell S., Hamilton R., Kaines A., Egan C., Bunce C et al. Macular perfusion determined by fundus fluorescein angiography at the 4-month time point in a prospective randomized trial of intravitreal bevacizumab or laser therapy in the management of diabetic macular edema (bolt study), *Retina*, 2010, 1(1);1-6.
- 4- Seo JW., Park IW., Intravitreal Bevacizumab for treatment of diabetic macular edema, *Korean J Ophthalmol*, 2009.
- 5- Stefánsson E., Diabetic macular edema, *Saudi Journal of Ophthalmology*, 2009, 23(2);143-148.
- 6- Faghihi H., Wahedi A., Riyazi M. (et al): intravitreal injection of triamcinolone for the treatment of diabetic macular edema resistant to laser. *The journal of BINA ophthalmology*:1385, pp. 132-140, vol. 12 (2)
- 7- Bhagat N., Grigorian RA., Tutela A., Zarbin MA., PhD. Diabetic Macular

- Edema: Pathogenesis and Treatment, Survey of Ophthalmology, 2009, 54(1);1-32 .
- 8- Nagasawa T., Naito T., Matsushita S., Sato H., Katome T., Shiota H., Efficacy of intravitreal bevacizumab (avastin) for short-term treatment of diabetic macular edema, the journal of medical investigation, 2009, 56.
 - 9- Eshg Abadi A., Riyazi M.: Diabetic Macular Edema. The scientific journal of NOOR, 1389, p.1-16, vol. 15
 - 10- Kumar A., Sinha S., Intravitreal bevacizumab (Avastin) treatment of diffuse diabetic macular edema in an Indian population, Indian J Ophthalmol, 2007, 55(6).
 - 11- Bhisitkul RB. Vascular endothelial growth factor biology: clinical implications for ocular treatments. Br J Ophthalmol , 2006;90. 1542- 1547.
 - 12- Forte R., Cennamo G., Vecchio EC., Tenore R., Aufiero B., Bevacizumab in macular edema, Retina, 2009, 29.

2/15/2021