



Estimation of Toxicity level of three different Herbal Bitters (Confam, G. Winco and 1960 Roots) on some Serum Lipid Profile parameters and the Heart of Wister Albino Rats

George Adieboye Oforibika¹ and Diepiriye Adokiye Oforibika²

¹Department of Science Laboratory Technology, School of Science and Technology, Captain Elechi Amadi Polytechnic, Port Harcourt, Nigeria.

²Department of medicine and Surgery, College of Medicine, University of Ibadan, Ibadan, Nigeria.
oforibikaa@yahoo.com

Abstract: The aim of this research is to estimate the toxicity level of three different herbal bitters (Confam, G. Winco and 1960 Roots) on some serum lipid profile parameters and the heart of Wister albino rats. A total of 40 rats were randomly divided into 4 groups labeled A, B, C and D and kept in a well ventilated room. Group A served as control and these rats were treated with distilled water. Rats in the groups B, C, and D were treated with 3 different doses of the bitters (20, 30 and 40mL/Kgbw) respectively. The drugs were administered once daily for 10 and 21 days consecutively. Animals were sacrificed 24 hours after the last treatment. Blood samples were collected into heparinized sample bottles for analysis. There was no significant difference in the results obtained. There was dose dependent decrease in serum triglyceride and cholesterol levels. Pathological changes were seen on histology at the highest concentrations and longest durations of the herbal bitters. This study thus shows that high amounts of herbal bitters are lipid lowering and have a direct negative effect on myocardial tissue.

[Oforibika G. A. and Oforibika, D. A. **Estimation of Toxicity level of three different Herbal Bitters (Confam, G. Winco and 1960 Roots) on some Serum Lipid Profile parameters and the Heart of Wister Albino Rats.** *Life Sci J* 2020;17(6):44-49]. ISSN: 1097-8135 (Print) / ISSN: 2372-613X (Online). <http://www.lifesciencesite.com>. 5. doi:[10.7537/marslsj170620.05](https://doi.org/10.7537/marslsj170620.05).

Keywords: Herbal bitters, Confam, G. Winco, 1960 Roots, serum lipid profile, Albino rats.

1. Introduction

The term “bitters” as it is used presently, is a beverage, often alcoholic, flavoured with herbal essences that gives it a bitter or bittersweet flavour. The generic term applies to all bitter liquors and herbal bitters. Bitters are produced from herb and root extracts, primarily from the narcotic components of tropical and subtropical plants and spices. They are usually dark in colour and valued for their ability to promote appetite and digestion hence their use as patent medicine and as aid in digestion and as flavouring in cocktails. Bitters are made up of numerous groups of chemical compounds extracted from the herbs and roots (medicinal plants) that have the common characteristic of a bitter taste (Hoffman, 2002). Bitters have been claimed to help heal piles/haemorrhoids and improve sexual function. Enhance blood circulation, purification of blood by the kidneys, blood pressure regulation through arterial dilatation and prevent formation of kidney stones, cleanse the colon of impurities and have also been said to possess anti-tumour properties and especially protects against colo-rectal cancers (Hussain *et al.*, 2011; Osamor and Owumi, 2010). They are also said to have anti-inflammatory, antibiotic and antifungal

properties. Bitters have also been said to ensure good digestion of fats and oils, and proper functioning of the liver in excretion, reduce accumulated fat (triglycerides) and cholesterol levels thereby conferring on it hypolipidaemic properties (Mendie, 2009; Ekor *et al.*, 2010). They are said to reduce excess body fat and promote healthy weight loss, act as a liver tonic and body detoxifier; being hepatoprotective and enhancing its functions generally and helping in body detoxification. Bitters act on the pancreas and liver, help in cell division and growth of the pancreas thereby helping to normalizing blood sugar and promote the production and release of pancreatic enzymes. Some are even said to have hypoglycaemic properties (Jimmy and Udofia, 2014). This is what drove the researcher to carry out this study to evaluate the effects of these bitters on the triglyceride, cholesterol levels and the heart. The aim of this research was to estimate the toxicity level of three different herbal bitters (Confam, G. Winco and 1960 Roots) on some serum lipid profile parameters and the heart of Wister albino rats.

2. Materials and Methods

Confam bitter used in this study was gotten from Mile 3 market, Diobu Port Harcourt. G. Winco, 1960 roots. Specimen (animal) used for the experiment: forty (40) albino rats were purchased from animal house of the Department of Biochemistry, University of Port Harcourt, Choba Park. The animals were fed with rat pellets, water and libitum. Chemicals and reagents: all chemicals and reagents used in this study were obtained from Randox Laboratories UK. Preparation of Drug solution for administration: 20ml/kg, 30ml/kg and 40 ml/kg of the preparation was given to the rats each day after weighing depending on their respective groups. Experimental procedure: a total forty (40) albino rats of weight range (124-194g/BW) were randomly divided into four groups labeled A, B, C, D and E where group A served as control and rats (n=2rats/dose) were treated with distilled water. Rats in groups B, C and D (n = 2 rats/dose) were orally treated with 3 different doses of Confam (20, 30 and 40ml/kgBW), G. Winco (20, 30 and 40ml/kgBW) and 1960 (20, 30 and 40ml/kgBW) roots for 10 and 21days respectively. Animals were sacrificed twenty four (24) hours after last treatment.

2.1 Collection of Blood and Preparation of Serum

The rats were withdrawn from the cages in each of the group twenty four (24) hours after the last administration of the drugs for 10 and 21 days and placed in a desiccator containing cotton wool soaked in chloroform to anaesthetize the rats. The blood samples were obtained by cutting the jugular vein of the rat on the neck by means of surgical blade and put in anticoagulant sample bottles smeared with lithium-heparin and fluoride oxalate. The blood samples were spun at 5000rpm using MSE Centrifuge to obtain plasma. The animal was dissected and only the liver was collected for pathological studies.

2.2 Measurement of Cholesterol

Three cuvettes were labeled standard, sample and reagent blank. 10µl of distilled water, standard and sample (serum) was pipetted into the three cuvettes as labelled. 1000µl of the reagent was pipette into all the cuvettes, mixed and incubated in a water bath for 10minutes at 25°C. Absorbance of the sample against the reagent blank was taken using a spectrophotometer at a wavelength of 500nm within 60 minutes.

$$\text{Conc. of Cholesterol} = \frac{\text{Absorbance of sample} \times \text{Conc. of standard}}{\text{absorbance of standard}}$$

2.3 Measurement of Triglycerides

Three test tubes were labeled reagent blank, standard and samples. They were placed in a test tube rack. 5ul of sample (serum) was pipetted into the sample and blank test tubes respectively. 0.5ul of

reagent solution was then added to the three testubes, mix and incubated for 10 minutes at 25°C. Absorbance was read at 546nm within 60 minutes.

Calculation of Triglycerides:

$$\frac{\text{Absorbance of sample} \times \text{concentration of standard (m/mol)}}{\text{Absorbance of standard (m/mol)}}$$

2.4 Histological Procedures and Analysis

The heart was cut on slabs about 0.5cm thick and fixed in 10% normal saline for a day after which they were transferred to 70% alcohol for dehydration. The tissues were passed through 90% alcohol and chloroform for different durations before they were transferred into two changes of molten paraffin wax for 20mins each in an oven at 57%. Several sections of the 5µm thick were obtained from a solid block of tissue and were stained with hematoxylin and eosin staining after which they were passed through a mixture of equal concentration of xylene and alcohols, following clearance of xylene, the tissues were oven dried. Photomicrographs were taken with a JVC colour video digital camera (JVC China) mounted on an Olympus light microscope (Olympus UK Ltd Essex, UK) to demonstrate cytoarchitecture of the heart.

3. Result and Discussion

In this study, serum triglyceride and cholesterol levels showed no significant difference when compared to control irrespective of dosage and duration of use. G. Winco showed a dose dependent decrease in serum cholesterol at 40ml/kg and at 10 days of administration Confam bitters showed a dose dependent decrease in serum cholesterol most evident at 40ml/kg and for 21 days. The other bitters showed variable responses. For serum triglycerides, there was dose dependent decrease at 10days of administration and most seen at 40ml/kg dose. Distorted cardiac tissues with heterogenous diameters were seen in all the bitters at 40ml/kg dose and at 10 days of administration. 30ml/kg of G. Winco also had similar occurrence. Same findings were seen at 21 days of administration in G. Winco and confam. The result from this study shows that these bitters have a dose dependent lipid lowering effect even in apparently healthy animals. This is supported by the study done by Aniagu *et al.* (2005) and Anionye *et al.* (2017) which reported significant reductions in serum cholesterol and triglycerides. This differs from the report of Anionye *et al.* (2017) who reported normal cardiac histology. This study shows that prolonged use of high amounts of these bitters are detrimental to the integrity of the cardiac tissue. Tables 1 and 2 shows the effects of local bitters on the cholesterol and triglyceride respectively.

Table 1: Effect of local bitters on cholesterol (mg/dL)

Control (distilled water)	Concentration	3.3±0.3 10days	2.5±0.3 21days
Confam	20ml/kg	3.0	2.7
	30ml/kg	3.0	2.5
	40ml/kg	2.8	2.0
1960 roots	20ml/kg	2.7	2.0
	30ml/kg	2.9	2.9
	40ml/kg	3.0	2.7
G. Winco	20ml	3.1	2.4
	30ml/kg	2.8	2.6
	40ml/kg	2.7	2.6

Table 2: Effect of local bitters on triglyceride (mg/dL)

Control (distilled water)	Concentration	0.6±0.3 10days	1.1±0.2 21days
Confam	20ml/kg	0.4	1.2
	30ml/kg	0.4	1.0
	40ml/kg	0.2	1.1
1960 roots	20ml/kg	0.6	1.2
	30ml/kg	0.4	1.1
	40ml/kg	0.3	1.2
G. Winco	20ml	0.4	1.0
	30ml/kg	0.5	1.1
	40ml/kg	0.5	1.2

3.1 Result on day 0 (control)

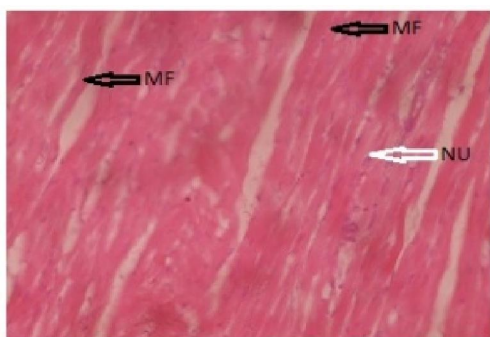


Figure 1 (20): Photomicrograph of cardiac tissue treated with distilled

water showing normal

myocardial fibres branching, weaving and merging with each other forming a continuous multinucleated mass (control)

3.2 Result on 10 days of administration

Figure 2: L-R: 21: photomicrograph of cardiac tissue treated with confam 20ml/kg showed normal myocardial fibres that are of homogenous diameter, polygonal shaped, with peripheral nuclei and non-fragmented sarcoplasm. 22: photomicrograph of cardiac tissue treated with confam 30ml/kg showed normal myocardial fibre of homogenous diameter, branching, weaving and merging with each other forming a continuous multinucleated mass. 23: photomicrograph of cardiac tissue treated with confam 40ml/kg showed myocardial fibres that are heterogenous in diameter with clustered nuclei from disrupted sarcoplasm.

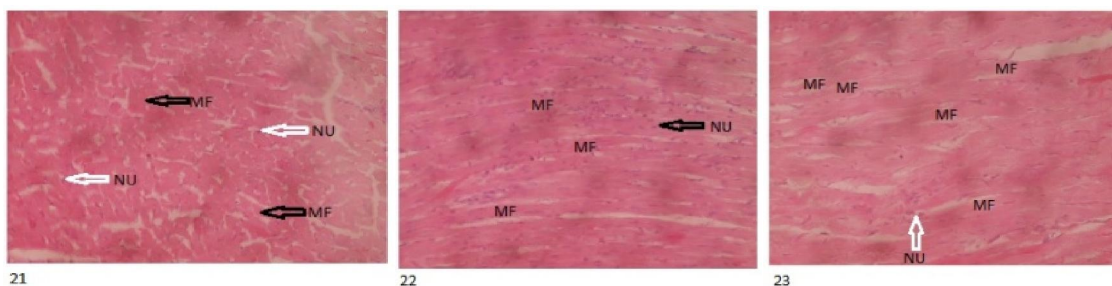


Figure 2 (21-23): Photomicrograph of cardiac tissue treated with different herbal bitters

L-R: 21: photomicrograph of cardiac tissue treated with 1960 roots 20ml/kg WITH normal myocardial fibres that are of homogenous diameter, polygonal shaped, with peripheral nuclei and non-fragmented sarcoplasm. 22: cardiac tissue treated with 1960 roots 30ml/kg showed myocardial fibres that are

heterogenous in diameter with clustered nuclei from disrupted sarcoplasm. 23: photomicrograph of cardiac tissue treated with 1960 roots 40ml/kg showed histologically distorted cardiac tissue and congested capillaries.

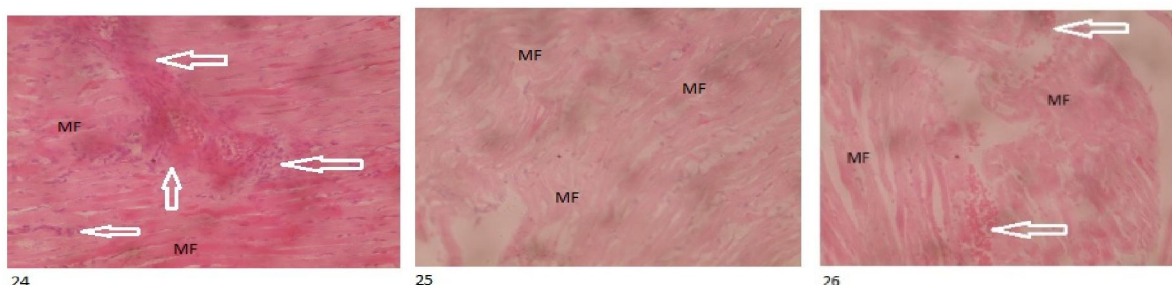


Figure 3 (24-26): Photomicrograph of cardiac tissue treated with the different herbal bitters

L-R: 24- photomicrograph of cardiac tissue treated with G. Winco 20ml/kg showed normal myocardial fibres branching, weaving and merging with each other forming a continuous multinucleated mass. 25: photomicrograph of cardiac tissue treated with G. Winco 30ml/kg showed abnormal myocardial

fibres that are of heterogeneous diameter with fused nuclei due to fragmented sarcoplasm (shown by arrows). 26: photomicrograph of cardiac tissue treated with G. Winco 40ml/kg showed abnormal myocardial fibres that have fused nuclei due to fragmented sarcoplasm (shown by arrows).

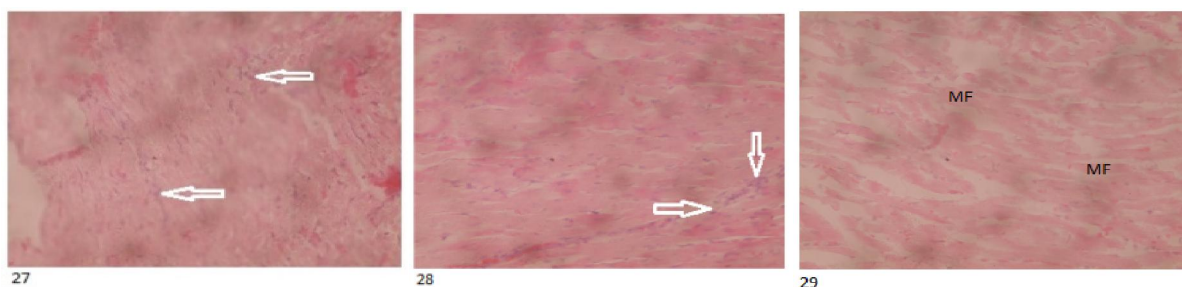


Figure 4 (27-29): Photomicrograph of cardiac tissue treated with the different herbal bitters

3.3 Result on 21 days of administration

L-R: 62: photomicrograph of cardiac tissue treated with confam 20ml/kg showed normal myocardial fibres branching, weaving and merging with each other forming a continuous multinucleated mass. 63: photomicrograph of cardiac tissue treated with confam 30ml/kg showed normal myocardial

fibres branching, weaving and merging with each other forming a continuous multinucleated mass. 64: photomicrograph of cardiac tissue treated with confam 40ml/kg showed myocardial fibres that are heterogeneous in diameter with distorted cardiac fibres.

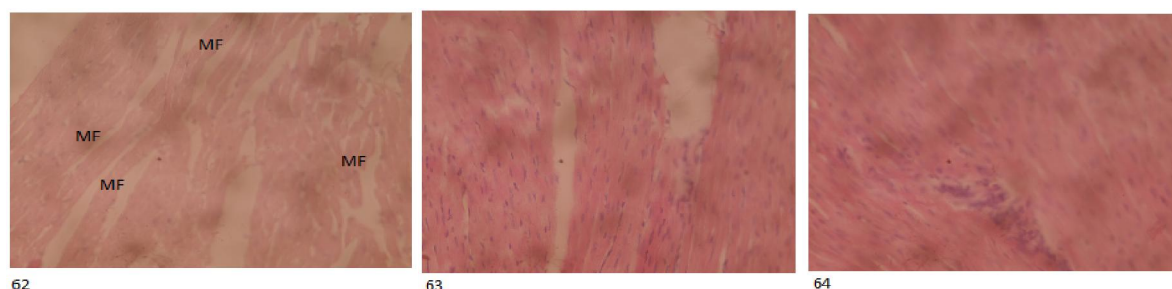


Figure 5 (62-64): Photomicrograph of cardiac tissue treated with the different herbal bitters

L-R: 62: photomicrograph of cardiac tissue treated with 1960 roots 20ml/kg showed normal myocardial fibres branching, weaving and merging with each other forming a continuous multinucleated mass. 63: photomicrograph of cardiac tissue treated with 1960 roots 30ml/kg showed normal myocardial

fibres branching, weaving and merging with each other forming a continuous multinucleated mass. 64: photomicrograph of cardiac tissue treated with 1960 roots 40ml/kg showed normal myocardial fibres branching, weaving and merging with each other forming a continuous multinucleated mass.

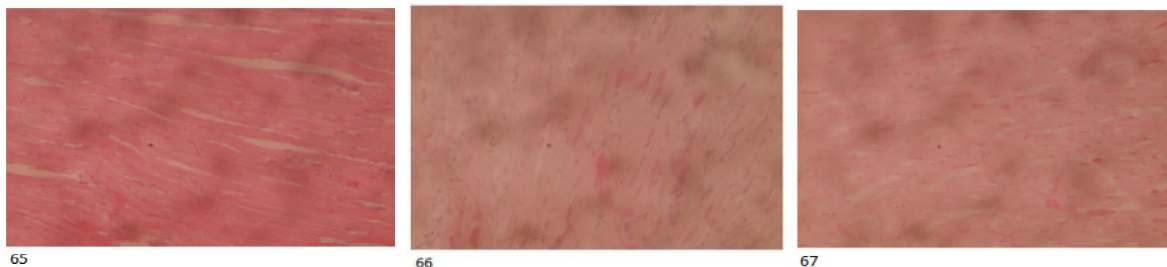

Figure 6 (65-67): Photomicrograph of cardiac tissue treated with the different herbal bitters

L-R: 65: photomicrograph of cardiac tissue treated with G. Winco 20ml/kg showed normal myocardial fibres branching, weaving and merging with each other forming a continuous multinucleated mass. 66: photomicrograph of cardiac tissue treated with G. Winco 30ml/kg showed normal myocardial

fibres branching, weaving and merging with each other forming a continuous multinucleated mass. 67: photomicrograph of cardiac tissue treated with G. Winco 40ml/kg showed myocardial fibres that are distorted, heterogeneous in diameter with hypertrophic nuclei.

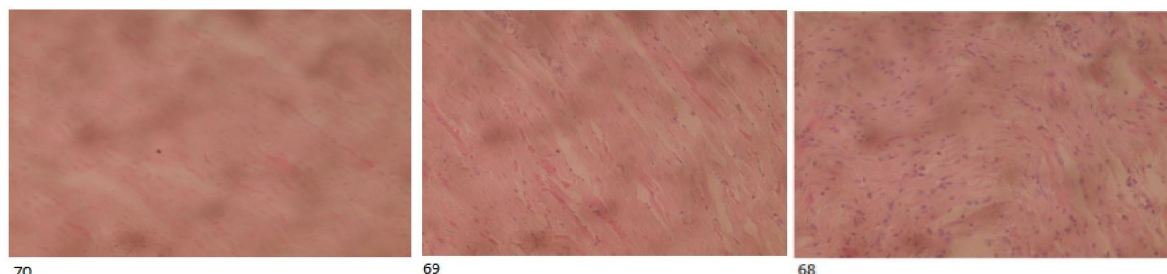

Figure 7 (68-70): Photomicrograph of cardiac tissue treated with the different herbal bitters

4. Conclusion

There was dose dependent decrease in the serum triglyceride and cholesterol levels. This study thus shows that high amounts of herbal bitters are lipid lowering and have a direct negative effect on myocardial tissue. There is a relationship between high serum cholesterol levels and the incidence of atherosclerosis and cardiovascular disease, the observed effect of these herbal bitters is therefore a desired positive effect. Histopathological changes in the heart were evident at the highest concentrations and longest durations of two out of the three bitters used in this study.

References

1. Aniagu S., Nwinyi CF, Akumka D.D., Ajoku AG, Dzarma S, Izebe KS, Ditse M, Nwaneri EC, Wambebe C, Gamaniel K. (2005). Toxicity studies in rats fed nature cure bitters. *African Journal of Biotechnology*, 4(1):72-78.
2. Anionye JC, Onyenek, EC, Eze GI, Edosa RO. (2017). Evaluation of the effect of super bitters on albino rats. International digital organization for scientific research. *IDOSR Journal of Applied Sciences*, 2(1): 41-58.
3. Ekor, M. A., Osumiga, O. A., and Odewabi, A. O. (2010). Toxicity Evaluation of yoyo bitters and fields Swedish Bitters Herbal preparations following Subchronic Administration in Rats.

- American Journal of Pharmacology and Toxicology*, 5 (4): 159-166.
4. Hoffmann, D. (ed.) (2002). *Holistic Herbal. A safe and Practical Guide to Making and Using Herbal Remedies*. (1st Edn). Harper Collins Publishers, Australia. Pp. 1-256.
 5. Hussain, I, Ullah, R, Khurram, M, Ullah, N, Baseer, A, Khan, FA, Khattak, MR, Zahoor, M, Khan, J and Khan, N. (2011). Phytochemical analysis of selected medicinal plants. *African Journal of Biotechnology*, 10(38): 7487-7492.
 6. Jimmy EO. Udofia AJ. (2014). Yoyo bitters, a potent alternative herbal drug in the treatment of diabetes. *International Journal of Innovative Medicine and Health Science*, 2: 1-5.
 7. Mendie, U. E. (ed.) (2009). *Yoyo Bitters Clinical Report*. Abllat Nigeria Company Limited. Lagos, Nigeria. Pp: 1-5.
 8. Osamor PE, Owumi BE. (2010). Complementary and alternative medicine in the management of hypertension in an urban Nigerian community. *BMC Complement Altern Med*. 10(1): 36-44.

6/20/2020