



Diagnostic Techniques Of Infectious Bursal Disease Virus: A Review

Abde Aliy¹, Solomon Shiferaw², Dereje Shegu¹, Bayeta Senbeta¹, Chala Guyassa¹, Abdela Bulbula¹

¹National Animal Health Diagnostic Center (NAHDIC), Sebeta, Ethiopia

² Ambo University, College of Agriculture and Veterinary science, Ambo, Ethiopia

abde.aliy@yahoo.com/didigabruma@gmail.com, Telephone: +251917853590

Summary: Infectious bursal disease, also known as Gumboro disease is an acute highly contagious viral disease of young chickens and characterized by destruction of the lymphoid cells of the bursa of fabricus due to damage of bursa of fabricus the diseases causes severe immunosuppressant and impaired growth of juvenile chickens. The virus occurs worldwide, and outbreaks of disease occur frequently, and various variants occur each with a different virulence. To identify existing and emerging antigenic variants, molecular epidemiology of the virus should be studied regularly; Molecular diagnostic techniques should be used to identify subtypes or patho-types and Vaccine strain selection should be based on the result of molecular detection and characterization of existing Infectious Bursal Disease virus. Reverse transcriptase polymerase chain reaction assays have greater versatility and are more sensitive and specific. So, polymerase chain reaction based molecular diagnostic techniques are more efficient techniques in virus diagnosis and identification of different strains of Infectious Bursal Disease virus. The objective of this paper is therefore to review various diagnostic techniques of infectious bursal disease virus detection and emphasizing the significance of recent diagnostic techniques for strain differentiation which are essential for correct and early detection of the diseases.

[Abde A, Solomon S, Dereje S, Bayeta S, Chala G and Abdela B. **Diagnostic Techniques Of Infectious Bursal Disease Virus: A Review.** *Life Sci J* 2020;17(6):1-12]. ISSN: 1097-8135 (Print) / ISSN: 2372-613X (Online). <http://www.lifesciencesite.com>. 1. doi:[10.7537/marslsj170620.01](https://doi.org/10.7537/marslsj170620.01).

Key words: Diagnostic techniques, Immunosuppression, Infectious Bursal Disease, Reverse Transcriptase Polymerase Chain Reaction, Strain, Virus

1. Introduction

Poultry production is one segment of livestock production and an important agricultural activity in almost all developing communities in Africa and elsewhere, and also it is the fastest growing components of global agricultural demands because it has a peculiar privilege to contribute to the sector as well as to improve the living standards of the poor livestock keepers (Fisseha, 2009; Moyo and Swanepoel, 2010). Poultry are easily accessible, even to the poorest households or those with a lack of able-bodied workers, as they require minimal land, labor or financial inputs (Bettridge *et al.*, 2014).

Poultry can scavenge for food, and do not compete for food resources with humans. They are normally in close proximity to the household, enabling them to be managed by women and children while placing few additional burdens on these groups, as they may be kept under minimal supervision (Bettridge *et al.*, 2014). In rural areas, chickens serve as a source of cash used to buy clothes, school supplies, medical costs, etc for children and women (Hailemichael *et al.*, 2016).

One of the diseases that are of growing concern in poultry is Infectious bursal disease (IBD) that causes diseases in juvenile chicken and heavy loss in poultry (Tomas *et al.*, 2015). The virus occurs worldwide, and outbreaks of disease occur frequently, and various variants occur, classical (cvIBDV) (produce clinical signs), antigenic variant (avIBDV) (do not produce overt clinical signs, but cause immunosuppression) and very virulent (vvIBDV) (per acute onset of severe clinical disease with high mortality), each with a different virulence (Zhao *et al.*, 2012; Tomas *et al.*, 2015; Enurah *et al.*, 2018).

Small and large-scale chicken farms are rapidly growing in Ethiopia. Accompanying intensification of poultry farming, there is occurrence of epidemics of newly introduced diseases and/or epidemics of endemic diseases (Hailemichael *et al.*, 2016). In Ethiopia, constraints associated with the infectious diseases are challenging factors and IBD is the one that become to cause frequent outbreaks and a serious threat and a challenge to the juvenile poultry industry (Mazengia, 2012).

Infectious bursal disease (IBD), also known as Gumboro disease is an acute highly contagious viral

disease of young chickens (< 6 weeks) and characterized by destruction of the lymphoid cells of the bursa of fabricus with severe immunosuppressant (<3weeks) and impaired growth of young chickens (Chakman,2015; Beenish *et al.*, 2016). Primary target organ of the virus is BF which is functional and well developed in young chickens and that is why the disease is common in young chickens. In acute cases it is associated with mortalities, hemorrhages and also bursal damage (Minalu *et al.*, 2015). Immunosuppressant increases susceptibility to other infectious diseases. IBDV cause heavy mortality and morbidity and the emergence of antigenic variant as well as very virulent (vv) strains in vaccinated flocks considerably stimulated research efforts on both, IBD and IBDV (Yao and Shijun, 2017).

The infectious bursal diseases virus (IBDV) presents a certain number of characteristics that are important in the diagnosis and control of IBD. Among these the disease is caused by a small, non-enveloped virus, highly resistant to the external environment, and additionally the virus has a high mutation rate and may thus give rise to viruses of modified antigenicity or increased virulence, the number of vvIBDV strains and their reassortants have continuously increased and the strains have become epidemic and posed a great threat to the poultry industry with the vaccination strategy, making the prevention and control of IBD more challenging (Yao and Shijun, 2017; Aregitu, 2018).

Detection and strain identification of IBDV is important because antigenic subtypes found within serotype make it necessary to tailor vaccination programs to the antigenic type found in the bird's environment. Conventional virus isolation and characterization are not practical for routine diagnosis, for detection and strain identification of IBDV (Jackwood, 2018).

Reverse transcriptase polymerase chain reaction (RT-PCR) assays have greater versatility and are more sensitive and specific. Therefore, PCR-based molecular diagnostic tools are more efficient in virus diagnosis and identification of different strains of IBDV (Rekha *et al.*, 2014). The objective of this paper is therefore, to review various diagnostic techniques of infectious bursal disease virus detection and emphasizing the significance of recent diagnostic methods which are essential for correct and early detection of the disease.

2. Literature Review

2.1. Etiology

Infectious bursal disease (IBD) is caused by a virus that is a member of the genus *Avibirnavirus* of the family *Birnaviridae* (Ingrao *et al.*, 2013). Two serotypes of IBDV are recognized. These are

designated serotypes 1 and 2. Both serotypes can be differentiated by cross-neutralization assays. Clinical disease has been associated with only serotype 1 and all commercial vaccines are prepared against this serotype (Dey *et al.*, 2019). Antigenic variants of IBD serotype 1 have been described and these may require special vaccines for maximum protection. Very virulent strains of classical serotype 1 are now common and are causing serious disease in many countries (Cubas-Gaona *et al.*, 2018).

Serotype 1 viruses replicate in the bursa of fabricus and some serotype 1 viruses cause clinical disease in chickens. Antibodies or virus are sometimes found in other avian species, but no signs of infection are seen or subclinical. Serotype 2 viruses have been detected from the respiratory tract of turkeys, cloacal swabs of ducks or in the bursa of fabricus of chickens. Antibodies against serotype 2 viruses are very widespread in turkeys and are sometimes found in chickens and ducks (OIE manual, 2016).

2.2. Morphology and genome of the virus

Infectious bursal disease virus (IBDV) is a double strand RNA virus (dsRNA) and a non-enveloped, icosahedral capsid. The genome of the IBDV is bi-segmented and divided into segment A and B (Fig.1). The larger open reading frame 1 (ORF1) of segment A encodes for a 110 kDapolyprotein which auto-catalytically splices into viral proteins VP2 (48 kDa), VP3 (33–35 kDa) (Fig.2) and VP4 (24 kDa) (Dey *et al.*, 2019). Segment A contains two partially overlapping open reading frames (ORFs) that encode the major components of the virus. The first ORF encodes the nonstructural viral protein VP5 (17 kDa) and the second one encodes a polyprotein precursor (pVP2–VP4–VP3, 110 kDa) that can be cleaved by VP4 (28 kDa) in Trans to release pVP2 (512 residues, 54.4 kDa) and VP3 (32 kDa). Both VP4 and the puromycin-sensitive amino peptidase (PurSA) cleave the pVP2 at its C-terminus to generate the intermediate pVP2 (452 residues), which is further processed by VP2 itself to generate the mature VP2 (441 residues). VP3 acts as a scaffold protein that binds both the viral double-stranded RNA and VP1 (Irigoyen *et al.*, 2012).

Viral Protein 2(VP2) and Viral Protein (VP3) are the major structural proteins, constituting 51% and 40% of the virion, respectively. The mature VP2 with a variable amount of pVP2 (452 residues) and VP3 assemble the single shelled capsid of IBDV. The released peptides arising from the cleaved pVP2 are also assembled in the virus, contributing to the virus viability and cell membrane perforation. Unlike segment A, segment B is the short RNA measuring 2.8 kb and it encodes VP1 (97 kDa), an RNA-dependent RNA polymerase (RdRp) (Mertens *et al.*, 2015; Yao and Shijun, 2017).

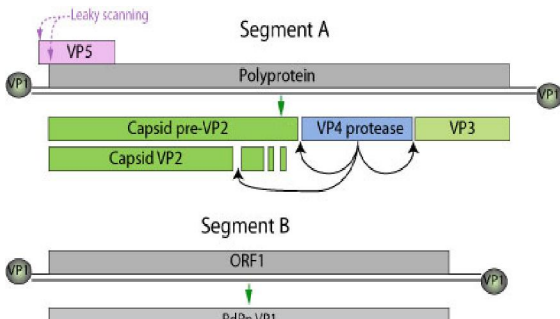


Figure 1: Genome structure of IBDV
Source: Aregitu (2018)

The 2 segments (A and B) encode for 5-6 proteins. VP1 is found in a free form and covalently attached at the 5' genomic RNA end (VPg). Segments size is about 2.3-3 kb. Genome total size is about 6 kb. Source: Aregitu (2018)

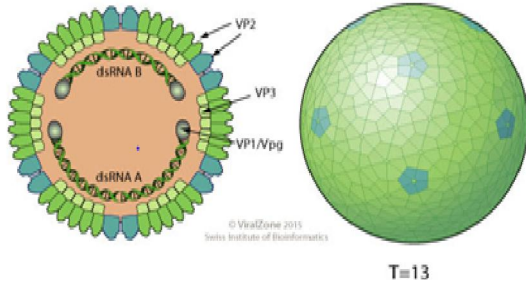


Figure 2: Morphology of IBDV
Source: Aregitu (2018)

2.3. Physico-chemical characteristics

The virus is non-enveloped and quite resistant to physical and chemical agents, resistant to: pH conditions of 2–11, but it is inactivated at pH 12. Due to this ability of stability and hardness, it persists in poultry premises even after thorough cleaning and disinfection, for up to 4 weeks in the bone marrow of infected chickens. The virus has been shown to remain infectious for 122 days in a chicken house, and for 52 days in feed, water and feces (Samson, 2018).

A marked reduction in infectivity of the virus was observed after treatment with 0.5% Formalin for 6 hours. The virus remained unaffected by ether, chloroform, phenol, thiomaesal, Staphene and Hyamine 2389 treatments. The virus survived treatments with various concentrations of three disinfectants (an iodine complex, a phenolic derivative and a quaternary ammonium compound) for a period of 2 minutes at 23°C, only the iodine complex had any deleterious effects. The virus was inactivated by exposure for 1 hour to 1% formalin, 1% cresol and 1% phenol. It remained stable at 60°C for 90 minutes and was still infectious at room temperature for approximately for 21 days (Minalu *et al.*, 2015).

2.4. Epidemiology

2.4.1. Distribution

In recent years, very virulent strains of IBDV (vvIBDV) have emerged in Europe, Latin America, South-East Asia, Africa and the Middle East, causing severe mortality in chicken and heavy loss in poultry. The IBDV can be spread through contaminated equipment, litter, caretakers, feed, and possibly by aerosol. IBDV can survive for 36 h in the infected chicken blood and dead birds are considered to be the vehicle for the transmission of this disease to new farms (Zhao *et al.*, 2012). Classical IBDV have traditionally affected poultry worldwide ever since the first outbreak of disease was reported from Delaware, Maryland and Virginia (Delmarva) region. By 1970, the disease had been reported from Canada, Mexico, Europe, Africa, the Middle East and Asia (Enurah *et al.*, 2018). Classic (cvIBDV), antigenic variant (avIBDV), and very virulent (vvIBDV) in Africa, Asia, Europe, South America, and Oceania. In North America and the Caribbean, only cvIBDV and avIBDV (Tomas *et al.*, 2015).

The African vvIBD types are tentatively subdivided into VV1 which includes IBDV strains from Nigeria, Ethiopia and Zambia, and VV2 with IBDV strains from Nigeria, Tanzania and Zambia. The VV3 subgroup contains IBDV strains from Asia, Africa, Europe and other countries (Jenberie *et al.*, 2013). Frequent outbreaks and occurrence of new strains of IBD became a challenge to the juvenile poultry industry in Ethiopia (Mazengia, 2012).

2.4.2. Host range

Although turkeys, ducks, guinea fowl, pheasants and ostriches may be infected, clinical disease occurs solely in chickens. Only younger chickens are usually clinically affected. Older chickens usually show no clinical signs. Severe acute diseases of 3 to 6 week old birds are associated with high mortality, and signs including prostration, diarrhea, and sudden death. A subclinical disease is common in 0- to 3-week-old birds (Aliyu *et al.*, 2016).

2.4.3. Transmission

Infected birds excrete virus in their dropping at least for 14 days. It is excreted in the faeces and then contaminates water, feed and litter, where it persists and from where it commonly spreads (Minalu *et al.*, 2015). The disease is transmitted through contaminated water, feed and droppings. The most common mode of infection is through the oral route of susceptible chickens and IBDV may spread through contaminated equipment (Nafi'u *et al.*, 2017).

Although aerosol route of the disease transmission exists, faeco-oral route is the major route by which susceptible chick can be infected (Tsegaye and Mersha, 2014). The disease spread very fast in deep litter management system due to free contact of

the infected and non-infected birds. Also in the deep litter, the birds have direct access to their droppings, and as such the feed and water can be contaminated by the droppings of infected birds (Aliyu *et al.*, 2016).

2.4.4. Risk factors

Poultry farms that receive visitors on the farm premises have higher risk of infection with IBDV, compared with farms that do not. It is notable that most of the visitors are related with poultry business (the person himself buy or sell the products or act as a middle man for other person), they have higher chance of visiting several farms per day. In this way, they are more likely to transmit infection from infected farm to healthy farm (Y. Cao *et al.*, 2013)

Some husbandry practices may favor the spread and maintenance of this economically important infectious disease, including: inappropriate sanitary conditions, nutritional deficiencies, continuous exposure to wild birds, absence of routine vaccination, rearing of different species of birds together, and mixing of chicken during transit and at points-of-sale in markets (Wahome *et al.*, 2017).

Sales of live poultry are related with quick dissemination of infections through slaughtering the birds, evisceration, haphazard disposal of visceral organs and feathers, and contaminated equipment (Surabhi and Sachin, 2015; Samson, 2018). Factors for example: chicken freely scavenging and mixing with other species like ducks, turkey and the chicken from the neighbors while searching for feed; and returning birds from the markets. These activities readily facilitated the transmission of IBDV in village chicken. The IBD virus can survive for long in the environment thus enhancing its transmissibility (Mutinda *et al.*, 2014).

Another risk factor of IBDV is 'workers live outside the farm premises'. Access of vendor vehicles on the farm premises was a risk factor. If the farm owner has no transport facilities, vehicles belonging to vendors enter farm premises to pick up products. Thus, these vehicles visit many farms per day (Y. Cao *et al.*, 2013). The course of conducting trade, the vendor may in advertently transmit infection from an infected site to a healthy (Shapiro *et al.*, 2015).

2.4.5. Morbidity and Mortality

Infectious bursal disease is the major health and production constraint of young chicken. IBD is acute, highly contagious globally occurring viral poultry disease. A flock will show very high morbidity with severe depression in most birds lasting for 5–7 days. Mortality rises sharply for 2 days then declines rapidly over the next 2–3 days due to short incubation period of the virus. Usually between 5% and 10% of birds die, but mortality can reach 30–40% or more with very virulent IBDV (vvIBDV) (OIE Manual, 2016).

3. Diagnostic Techniques

Isolation and identification of the agent provide the most certain diagnosis of IBD, but are not usually attempted for routine diagnostic purposes as the virus may prove difficult to isolate. Several methods are available for diagnosis depending on the objectives. In practice, laboratory diagnosis of IBD depends on detection of specific antibodies to the virus, or on detection of the virus in tissues, using immunological or molecular methods (Mansour *et al.*, 2015).

3.1. Clinical signs and pathological lesions

Diagnosis involves consideration of flock history, clinical sign and post mortem lesion. In infected chickens with infectious bursal disease pathological change observed at the bursa of fabricius is characteristic and histopathological investigations combined with the demonstration of viral antigen by immune histo chemistry confirm an IBDV infection (Minalu *et al.*, 2015). Only serotype 1 was pathogenic but there is no report of clinical disease caused by infection with serotype 2 virus which is non-pathogenic and IBD has not been reported to have any zoonotic potential (OIE manual, 2016).

Infectious bursal disease virus has short incubation period of 2-3 days and the infection generally last 5-7 days. One of the earliest sign of IBDV infection is the tendency for bird to engage in vent picking. Clinical sign are described as acute onset of depression, trembling, white and watery diarrhea, anorexia, prostration, ruffled feather, and vent feather. In severe cases, bird became dehydrated and in terminal stages subnormal temperature and death (Khan *et al.*, 2017).

The lesions observed in bird that are common to IBDV infection include anemia, hemorrhage in breast and leg musculature, darkened discoloration of pectoral muscles, occasional hemorrhage in thigh muscle and pectoral muscle (Singh *et al.*, 2015), increasing mucus in the intestine and renal changes (Dey *et al.*, 2019). In bird that die or are in advanced stage of the disease, kidneys frequently show swelling and pallor with accumulation of urates in the predominant lymphoid organ affected by IBDV, (Fig.3) (Aliyu *et al.*, 2016). The liver is usually swollen, with patchy congestion producing a mottled effect. In later deaths, the liver may be swollen and greenish, with areas of necrosis. The spleen is enlarged and the kidneys are swollen and congested, with a mottled effect. If lesions are observed, the virus should then be tested against a mono specific anti-IBDV serum in an embryo-revealed virus neutralization assay (Swati *et al.*, 2019).

Serotype 1 IBDV usually causes death in at least some of the embryos on primary isolation. Serotype 2 IBDV does not induce subcutaneous edema or hemorrhages in the infected embryos, but embryos are

of a smaller size with a pale yellowish discoloration (Awandka *et al.*, 2018). For the preparation of embryo-propagated stock virus or for subsequent passaging, embryos with lesions or embryos suspected

to be infected, respectively, are harvested aseptically. Their head and limbs are discarded and the main body is minced for the preparation a virus suspension (OIE Manual, 2016).

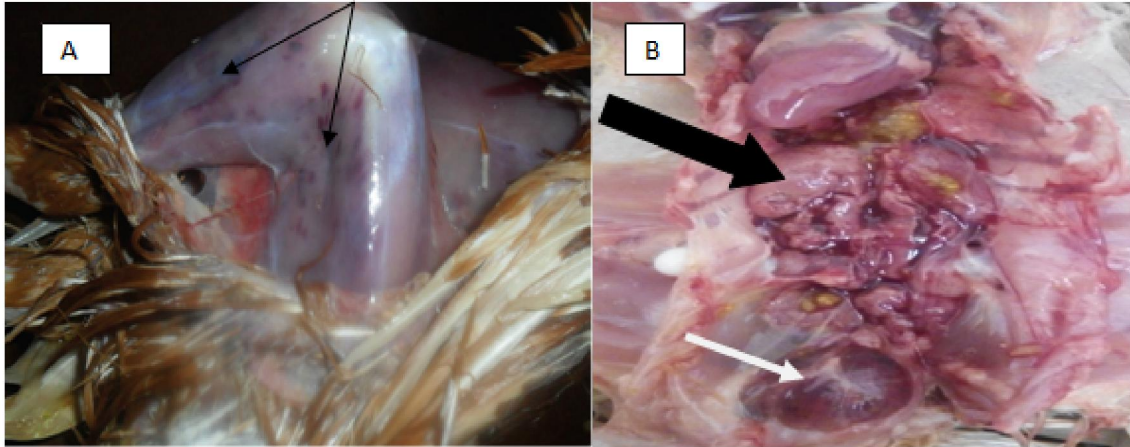


Figure 3: (Aliyu *et al.*, 2016).

(A) Echymotic hemorrhages on the thigh and leg muscles (B) enlarged pale kidneys (Black arrow), and edematous and hemorrhagic bursa of fabricius of 4-week-old brown pullets Source: (Aliyu *et al.*, 2016).

The tissues is processed and the 4 μ thick tissue sections are cut out of the paraffin embedded tissue blocks and stained with haematoxylin and eosin staining for routine histopathology (Singh *et al.*, 2015). Microscopic examination of tissues shows

moderate hemorrhages in the muscles and kidneys (Fig.4 (A) and (B)) and the spleen shows moderate lymphoid depletion in the lymphoid nodules. There is marked interfollicular edema and depletion of lymphocytes from the lymphoid nodules in the BFs (Fig.4 (B)). Other lymphoid nodules of the BF show degeneration and necrosis of lymphocytes and cystic cavitations with heterophil infiltrates (Fig.4 (B)) (Singh *et al.*, 2015).

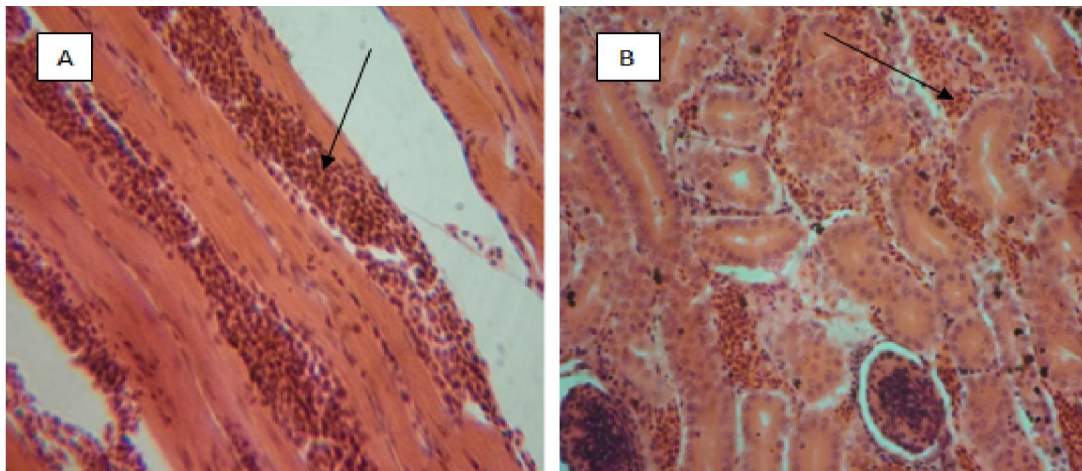


Figure 4: Pathological lesions of IBD in muscle and kidney Source: (Singh *et al.*, 2015).

The above figure indicates the hemorrhage (arrows) in muscle (A) and kidney (B) of 4-week-old chicks affected with infectious bursal disease stained with Hematoxylin and Eosine staining observed at 200X magnification.

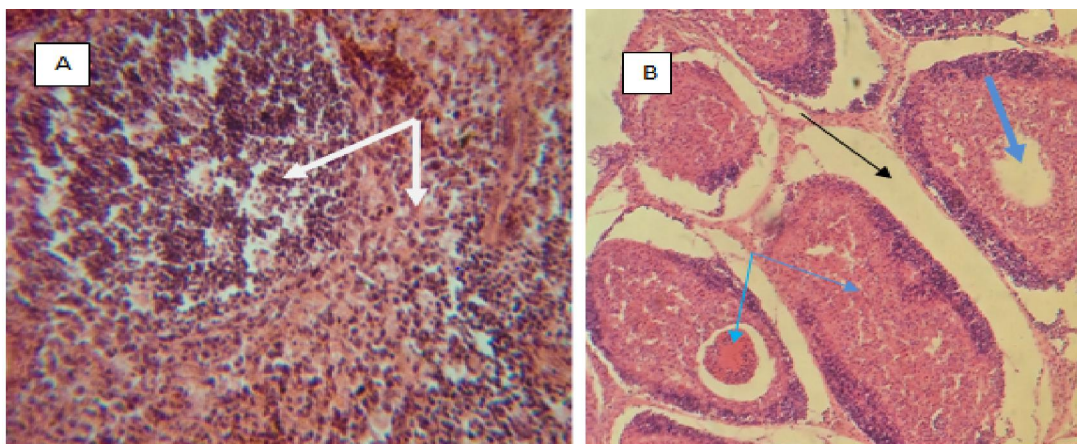


Figure 5: Pathological changes due to IBD in spleen and bursal follicle of chickens

Source: (Singh *et al.*, 2015).

The above figure showing photomicrographs of 4.3-week-old chicks affected with infectious bursal disease showing moderate lymphocytes depletion in the lymphoid nodules of the spleen (A), marked interfollicular edema (black arrow) and cystic cavitations and necrosis (blue arrows) in the medullar of bursal follicles (B) stained with hematoxylin eosin staining and observed at 200X magnification.

3.2. Virus Isolation on cell culture

Inoculate the sample to chicken embryo fibroblast (CEF) cultures (from a specific pathogen free (SPF) source) or DF-1 cell lines in 25 cm² flasks. Adsorb at 37°C for 30–60 minutes, wash twice with Earle's balanced salt solution and add maintenance medium to each flask. Incubate the cultures at 37°C, observing daily for evidence of cytopathic effect (CPE). This is characterized by small round refractive cells. If no CPE is observed after 6 days, discard the medium, then freeze–thaw the cultures and inoculate the resulting lysate into fresh cultures. This procedure may need to be repeated at least three times. If CPE is observed, the virus should be tested against monospecific IBDV antiserum in a tissue culture virus neutralization (VN) test (Rekha *et al.*, 2014).

The more pathogenic IBDV strains usually cannot be adapted to grow in CEF unless the virus has first been submitted to extensive serial passage in embryos (OIE manual, 2016). DF-1 cells arose spontaneously from line 0 (endogenous-virus negative) embryos and do not harbor any known endogenous viruses. The growth kinetics of DF-1 and CEF cells, and the optimal time of infection (TOI) by IBDV and their susceptibility to infection were compared (Mutinda *et al.*, 2015). A new effort has been made to study on the growth of DF-1 and CEF cell line and an estimated time of infection for enhancing increased virus production and infectivity titer were established. This approach would allow establishing an efficient cell line with increased virus

yields that may find application in vaccine production against IBDV (Rekha *et al.*, 2014).

Inoculate the sample into the yolk sac of five 6- to 8-day-old specific antibody negative (SAN) chicken embryos and on to the chorioallantoic membrane of five 9 to 11day old SAN chicken embryos. SAN embryos are derived from flocks shown to be serologically negative to IBDV (Mutinda *et al.*, 2015). Candle daily and discard dead embryos up to 48 hours post-inoculation. Embryos that die after this time are examined for lesions. Serotype 1 IBD produces dwarfing of the embryo, subcutaneous edema, congestion and subcutaneous or intracranial hemorrhages (Awandka *et al.*, 2018). In chickens the method has been used in the past but is no longer recommended due to animal welfare concerns. The bursa of chickens infected with virulent serotype 1 IBDV appear yellowish (sometimes hemorrhagic) and turgid, with prominent striations. Peribursal edema is sometimes present, and plugs of caseous material are occasionally found. The plicae are petechiated (Morla *et al.*, 2016).

The presence of lesions in the bursa of susceptible chickens along with the absence of lesions in immune chickens is diagnostic of IBD. The extent of bursal damage may vary considerably with the pathogenicity of the studied IBDV strain. However, as the samples submitted for virus isolation may vary in virus content, the extent of bursal damage observed in susceptible chickens at the isolation stage gives only a limited indication on strain pathogenicity. The bursae of chickens infected with serotype 2 IBDV do not exhibit any gross lesions (Awandka *et al.*, 2018).

3.3. Serological tests

3.3.1. Identification by Agar Gel Immuno-diffusion Test

The agar gel immune-diffusion (AGID) test is the most useful of the serological tests for the detection of specific antibodies in sera, or for detecting

viral antigen or antibodies in bursal tissue. AGID is the simplest, but least sensitive technique (Enurah, 2018). Results are obtained after an incubation period of 48 h. Variability in results may be due to the investigator, as well as the nature of the viral strain used as an antigen (Rai *et al.*, 2017).

The agar gel immune-diffusion (AGID) test can also be used to measure antibody levels by using dilutions of serum in the test wells and taking the titer as the highest dilution to produce a precipitin line. This can be useful for measuring maternal or vaccinal antibodies and for deciding on the best time for vaccination; however, this AGID quantitative determination has now been largely replaced by the ELISA (Sali, 2019). For detection of antigen in the bursa of fabricius by AGID, the bursa should be removed aseptically from chickens at the acute stage

of infection. The bursas are minced using two scalpels in scissor movement, and then small pieces are placed in the wells of the AGID plate against known positive serum. Freeze–thaw cycles of the minced tissue may improve the release of IBDV antigens from the infected bursal tissue, and the freeze–thaw exudates may be used to fill the wells (Jackwood, 2018).

The antigen and the antibody meet in agar gel and their diffusion is according to size, structure and charge. At the equivalence point of the antigen and antibody a precipitation arc is formed (Fig.6). In case of mixed antigen and antibody, the specifically reacting antibodies and antigens reach the equivalence point at different distances, so several arcs may be formed. Evaluation of the reaction is usually after 24 hours (OIE Manual, 2016; Rai *et al.*, 2017 and Sali, 2019).




Figure 6: precipitation lines formed by antigen-antibody reactions
Source: Enurah (2018).

The agar gel immune-diffusion (AGID) test has the advantage of simplicity, but the disadvantages of relatively low sensitivity in analyzing serum compared with ELISA and VN and slow formation of precipitin lines compared with other types of readouts (e.g., ELISA) (Rai *et al.*, 2017).

3.3.2. Identification by Immuno fluorescence

Sections of bursa are prepared using a microtome cryostat, dried at room temperature and then fixed in cold acetone. Fluorescent-labeled IBDV-specific antisera are applied to the sections, which are then incubated at 37°C for 1 hour in a humid atmosphere. At the end of the incubation period, they are washed for 30 minutes using phosphate-buffered saline (PBS), pH 7.2, and then rinsed in distilled water. The sections are mounted using buffered glycerol, pH 7.6, and examined by UV microscopy for IBDV-specific fluorescence (Singh *et al.*, 2015; OIE Manual, 2016)

3.3.3. Identification by Enzyme-Linked Immune Sorbent Assay

The detection of serotype 1 IBDV using an antigen-capture enzyme-linked immune sorbent assay,

ELISA plates are coated with IBDV-specific antibodies (Shekaro, 2016). Depending on the protocol, the capture antibody may be a mouse anti-IBDV monoclonal antibody (MAb), or a mix of such MAbs, or a chicken post-infectious anti-IBDV polyclonal serum. It has been suggested that AC-ELISAs using polyclonal antibodies may have a higher sensitivity (Wahome *et al.*, 2017).

Critical steps in the implementation or assessment of AC-ELISA are i) the need to perform extensive washings between each step of the reaction to keep background reactions low, ii) the requirement for known positive and negative samples to be included in each assay as controls, and iii) the need for both the capture and detection antibodies to positively react with all serotype 1 IBDV strains (i.e. neither capture nor detection should critically depend on IBDV antigenic variation that occurs among serotype 1 strains) (OIE Manual, 2016).

In antibody detection by indirect ELISA, The flat bottomed microtitre plates are coated with antigen. The principle of ELISA is that antibodies are attached to their specific antigen by linking an enzyme to an

antibody following the addition of the substrate. A serum sample is added and if there are specific antibodies they will bind to the antigen. If there is a positive sample, the antibody will attach and react with the substrate. Thus the positive samples will develop colour (Sali, 2019).

The enzyme-linked immune sorbent assay (ELISA) allows the quantification of antibodies to IBDV and is therefore used for monitoring the immune status of the chicken flocks to check response to vaccination, natural field exposure and decay of maternal antibody titer. The ELISA is the most rapid and sensitive method and presents the fewest variations due to the viral strain used as an antigen. It is economical, simple, and quick and tests a large number of samples at the same time and is adaptive to automation to computer software. However, ELISA cannot differentiate between the antibodies specific to the two serotypes. (Zegeye *et al.*, 2015; Shekaro, 2016).

The end-point (serum titer) is expressed as the reciprocal of the highest serum dilution that did not show CPE. To reduce test-to-test and operator-to-operator variation, a standard reference antiserum may be included with each batch of tests and the titer of the virus suspension must be reassessed in each new experiment using a sufficient number of repeats (wells) per virus dilution (OIE Manual, 2016).

3.3.4. *Virus Neutralization test*

Virus Neutralization (VN) tests are carried out in cell culture. The test is more laborious and expensive than the AGID test, but is more sensitive for detecting antibody. This sensitivity is not required for routine diagnostic purposes, but may be useful for evaluating vaccine responses or for differentiating between IBDV 1 and 2 serotypes. The test uses either SPF chicken embryo fibroblast cells, or a suitable continuous cell line (such as QT-35, BGM-70, MA-104, Vero or DF1), in conjunction with an adapted strain of IBDV (Morla *et al.*, 2016).

3.4. **Molecular diagnostic techniques**

3.4.1. *Reverse-transcriptase polymerase chain reaction*

Molecular techniques have been developed that allow IBDV to be identified more quickly than by virus isolation. This method can detect the genome of viruses that do not replicate in cell culture, because it is not necessary to grow the virus before amplification. The reverse transcriptase–polymerase chain reaction (RT-PCR) assay has been used by several laboratories to identify IBDV. Most researchers have focused on a variable sequence region of the VP2 gene that is known to encode one or more neutralizing epitopes of the virus (Awandkar *et al.*, 2018). RT-PCR is performed in three steps: extraction of nucleic acids from the studied sample, reverse transcription (RT) of

IBDV RNA into cDNA, and amplification of the resulting cDNA by PCR (Nurulfiza *et al.*, 2017). The two latter steps require that the user selects oligonucleotidic primers that are short sequences complementary to the virus-specific nucleotide sequence. Different areas of the genome will be amplified depending on the location from which the primers have been selected (Yamazaki *et al.*, 2016).

3.4.2. *Reverse-transcriptase polymerase chain reaction with Restriction Fragment Length Polymorphism*

The Reverse-transcriptase polymerase chain reaction (RT-PCR) products were digested with the restriction enzymes. The enzymes were used to generate RFLP patterns that distinguished viruses into molecular groups (Awandkar *et al.*, 2018). RT-PCR RFLP is very useful and rapid method for characterization and identification of existing and evolving strains of IBDV. This assay has been useful in placing vaccine strains of the virus into molecular groups. Within a molecular group, IBDV strains are related by ancestry (Khan *et al.*, 2017).

Furthermore, viruses within a molecular group have nucleotide and amino acid sequences that are relatively more alike compared with viruses in different molecular groups. The RT-PCR–RFLP procedures used to generate molecular groups of IBDV are designed to assess the nucleotide similarity or diversity among viruses (Khan *et al.*, 2017). The restriction fragments were electrophoretically separated in 2.0% agarose gels submerged in Tris-phosphate buffer. Gels were stained with ethidium bromide, and the DNA fragments were visualized under ultraviolet light (Yamazaki *et al.*, 2016).

3.4.3. *Real time Reverse-transcriptase polymerase chain reaction*

Viral RNA was extracted from the bursa homogenates using the QIAamp Viral RNA Mini Kit (Qiagen®, Hilden, Germany) according to manufacturer's instructions. Specific Primer and probe sequences for quantitative polymerase chain reaction (qPCR) analysis were used to amplify a 743bp fragment of the VP2 region of genome segment A were used (Nurulfiza *et al.*, 2017; Liu *et al.*, 2019).

TaqMan real-time RT-PCR assay to quantify viral load in the samples of IBDV infected chickens. Although very rapid and sensitive, this assay was not used to differentiate different strains of IBDV. Real-time RT-PCR with hybridization probe system is able to differentiate among IBDV strains. Real-time RT-PCR probe system employs fluorescence resonance energy transfer (FRET) to identify the RT-PCR products. There are two probes, one labeled with fluorescein isothiocyanate and the other with a Red 640 fluorophore. These probes are not destroyed during amplification, as they are in the TaqMan

system. Thus, they can be used after RT-PCR amplification to generate a melting temperature for each IBDV strain. The temperature at which one of the probes (usually identified as the mutation probe) will dissociate from the RT-PCR product (OIE Manual, 2016).

3.4.4. *Conventional Reverse-transcriptase polymerase chain reaction*

Conventional RT-PCR is currently the “gold standard” method for IBDV detection, but the need for both the thermo cycling system and an elaborate method of detecting the product after amplification is a disadvantage (Meng-Shiou Lee *et al.*, 2011).

The equipment and supplies necessary for conducting agarose gel electrophoresis were an electrophoresis chamber and power supply, gel casting trays, sample combs, electrophoresis buffer (Tris-EDTA 1% buffer), 6X loading buffer, Gel red and transilluminator (an ultraviolet light box). An agarose powder was mixed with Tris-EDTA 1% buffer to make 1.5% concentration, and then heated in a microwave oven until completely melted. PCR product containing loading dye was mixed with gel red and molecular ladder was added in separate well. 4 µl gel red with loading dye was added into 20 µl PCR products and then 10 µl of each PCR products were loaded in to separate well. 10 µl molecular marker (Ladder) was also loaded in the first lane. The lid and power leads were placed on the apparatus, and a current was applied. The electrophoresis was run for 1:20 hour at 120V. It was confirmed that whether the current was flowing by observing bubbles coming off the electrodes. The amplified fragment (amplicon) was visualized on 1.5% agarose and compared with the band of the molecular marker after the gel was placed on an ultraviolet transilluminator (Asmelash *et al.*, 2018).

3.4.5. *Reverse-transcriptase polymerase chain reaction Loop-mediated isothermal amplification*

Loop-mediated isothermal amplification (LAMP) is a novel technique that can rapidly amplify the target genome under isothermal conditions. Specifically, four to six primers are designed to recognize six to eight regions of DNA template, making the technique highly specific. Two more primers, forward loop primer (F loop) and backward loop primer (B loop) are integrated if acceleration of reaction is required (Mansour *et al.*, 2015). This newly devised process has no denaturation step, which makes it efficient as compared to conventional polymerase chain reaction PCR. It works under a constant isothermal temperature (60-65°C) as compared to different temperatures for denaturation, annealing and extension in PCR (Khan *et al.*, 2018).

Loop-mediated isothermal amplification is usually completed in 50-60 min while PCR takes 3-4 h based on different parameters for diagnosis of different samples. There is a need for highly purified sample or template DNA for proceeding with PCR, otherwise impurities show false results (Dhama *et al.*, 2014), while in case of LAMP, a robust and sensitive technique, samples can be integrated to the test. Loop-mediated isothermal amplification has been effectively applied for quick and sensitive detection of IBDV and other important pathogens (Meng-Shiou Lee *et al.*, 2011; Dhama *et al.*, 2014).

3.4.6. *Sequence and Phylogenetic analysis*

Following molecular detection DNA sequencing and phylogenetic analysis potentially allow differentiation of infectious bursal disease virus strains and comparative analysis with strain of viruses exists and important for understanding of evolutionary clue of the virus. To confirm the identity of the RT-PCR products as IBDV genome, the RT-PCR products were directly sequenced and analyzed (Nafi'u *et al.*, 2017). Gel containing RNA band of the expected size was excised and purified. The purified PCR products were sequenced directly using the Sequencing Kit and the genetic analyzer, assembly of the consensus sequences and alignment trimming was performed with the bioinformatics tools (Neven *et al.*, 2015).

Deoxyribonucleic acid (DNA) sequencing of the PCR product and analysis after sequencing can differentiate classic, variant, and vvIBDV strains because variant and vvIBDV have characteristic nucleotide and amino acid substitutions (Tomas *et al.*, 2015).

These methods potentially allow for more rapid, sensitive, and specific detection and differentiation of IBDV classic, very virulent, and variant subtypes. This approach is a valuable tool for molecular epidemiological studies on IBDV. The comparative analysis will indicate that if these viruses are genetically close to the vvIBDVs or classical strains (Kumar *et al.*, 2016).

4. **Conclusion And Recommendation**

Infectious bursal disease is an acute highly contagious viral disease of young chickens. There is a high variation in the genetic properties between strains of IBDV and these variations may play a role determining the antigenic and pathological characteristics of the viruses. Early detection and appropriate diagnostic techniques should be used for control and prevention of Infectious Bursal Diseases Virus. Diagnosis of the disease is performed with serological methods, virus isolation and molecular diagnostic methods for the detection of IBDV and differentiation of IBDV subtypes. Molecular methods have the advantages of being more rapid, more

sensitive, and less laborious than other assays. Strain identification can be accomplished using a variety of post-RT-PCR assays that are able to differentiate viruses into molecular groups that correlate with antigenic and pathogenic types. Following molecular detection DNA sequencing and phylogenetic analysis potentially allow differentiation of infectious bursal disease virus strains and comparative analysis with strain of viruses exists and important for understanding of evolutionary clue of the virus. Therefore, PCR-based molecular diagnostic tools are more sensitive and efficient in virus diagnosis and identification of different strains of IBDV. Based on these conclusions, the following recommendations are forwarded:

➤ To identify existing and emerging antigenic variants, molecular epidemiology of the virus should be studied regularly.

➤ Molecular diagnostic techniques should be used for routine diagnosis of early detection which is more efficient for control and prevention of the diseases.

➤ Vaccine strain selection should be based on the result of molecular detection and characterization of existing IBDV.

Acknowledgements:

All authors are grateful to the national animal health diagnostic center staffs for their support to prepare this paper.

Corresponding Author:

Mr. Abde Aliy

National Animal Health Diagnostic Center, Sebeta, Ethiopia

Telephone: +251917853590

E-mail address: abde.aliy@yahoo.com

References

1. Aliyu H. B, Sa'idu L, Jamilu A, Andamin A. D and Akpavie S. O (2016): Outbreaks of Virulent Infectious Bursal Disease in Flocks of Battery Cage Brooding System of Commercial Chickens. *Journal of Veterinary Medicine*, 10:1-7.
2. Aregitu M. (2015): Outbreak Investigation and Molecular Characterization of Infectious Bursal Disease Virus and Vaccine Immunogenicity trial in Ethiopia. MSc thesis, Addis Ababa University, College of Veterinary Medicine and Agriculture, Bishoftu, Ethiopia.
3. Aregitu M (2018): Review on infectious Bursal disease: Threat for Ethiopian Poultry industry. *e International Journal of Advanced Life Sciences*, 11:60-61.r.
4. Asmelash Tasew; Getaw Deresse; Esayas Gelaye; Molalign Bitew; Kibeb Legesse; Muuz Gebru and Mulugeta Ftiwi (2018): Molecular Characterization, Adaptation and Attenuation of Locally Isolated and Vaccinal Strain of Infectious Bursal Disease Virus for Development of Vero Cell-Based Infectious Bursal Disease Vaccine in Ethiopia. *Journal of Biology, Agriculture and Healthcare*, 8: 2224-3208.
5. Awandkar SP, Tembhum PA, Kesharkar JA, Kurkure NV, Chaudhari SP, Bonde SW and Ingle VC (2018): Identification and characterization of a novel infectious bursal disease virus from Outbreaks in Maharashtra Province of India. *Veterinary World*, 11: 1516-1525.
6. Beenish Zahid, Asim Aslam, Yasin Tipu, Tahir Yaqub and Tariq Butt (2016): Conventional and molecular detection of infectious bursal disease virus in broiler chicken. *Pakistan Journal of zoology*, 48: 601-603.
7. Bettridge J.M.; Lynch S.M. and Brena M.C. (2014): Infection-Interactions in Ethiopian village chickens. *Preventive Veterinary Medicine*, 117: 358-366.
8. Chakman, S. (2015): Epidemiology of infectious bursal disease in broiler birds of three districts in Bangladesh. *Asian Journal of Medical and Biological Research*, 1: 59-64.
9. Cubas-Gaona LL, Diaz-Beneitez E, Ciscar M, Rodríguez JF and Rodríguez D. (2018): Exacerbated apoptosis of cells infected with infectious bursal disease virus upon exposure to interferon alpha. *Journal of Virology*, 92: 64-68.
10. Dey S., Dinesh C Pathak, Narayan Ramamurthy, Hemanta Kumar Maity and Madhan Mohan Chellappa (2019): Infectious bursal disease virus in chickens: prevalence, impact, and management strategies. *Veterinary Medicine: Research and Reports*, 10:85-97.
11. Dhama K; Karthik K; Chakraborty S; Tiwari R; Kapoor S; Kumar A and Thomas P (2014): Loop-mediated isothermal amplification of DNA (LAMP): A new diagnostic tool lights the world of diagnosis of animal and human pathogens: a review. *Pakistan Journal of Biological Science*, 17: 151-166.
12. Enurah, C. Nwosuh, D. O. Ehizibolo, N. M. Sati, P. E. Emenna, I. Shittu, E. T. Obishakin and Nwagbo I. O (2018): Genetic Analysis of Infectious Bursal Disease Virus (IBDV) from a Farm in Vom, Plateau State, Nigeria. *Journal of Advances in Microbiology*, 12:1-6.
13. Fisseha Moges (2009): Studies on production and marketing systems of local chicken ecotypes in bureworeda, north-west Amhara Regional State, Ethiopia. MSc Thesis. Hawassa University, Hawassa, Ethiopia.

14. Hailemichael A., Gebremedhin B., Gizaw S. and Tegegne A (2016): Analysis of village poultry value chain in Ethiopia: Implications for action research and development. LIVES Working Paper 10. Nairobi, Kenya: International Livestock Research Institute. <https://doi.org/10.1155/2017/8359047>.
15. Ingraio F, Rauw F, Lambrecht B and van den Berg T. (2013): Infectious bursal disease: a complex host-pathogen interaction. *Developmental and Comparative Immunology*, 41:429–438.
16. Irigoyen, N; Caston, J.R. and Rodriguez, J.F (2012): Host Proteolytic Activity is Necessary for Infectious Bursal Disease Virus Capsid Protein Assembly. *Journal of Biology and Chemistry*, 287:24473-24482.
17. Jackwood, D.J. (2018): Overview of Infectious bursal disease in poultry. MSD Veterinary Manual, online at http://www.merckvetmanual.com/mvm/poultry/infectious_bursal_disease/overview_of_infectious_bursal_disease_in_poultry.html. Last accessed on 21-10-2018.
18. Jenberie, S., Lynch, S.E., Kebedea, F., Christley, R.M., Gelayea, E., Negussied, H., Asmaree, K. and Ayeleta, G. (2013). Genetic characterization of infectious bursal disease virus isolates in Ethiopia. *Acta Tropica*, 130: 39-43.
19. Khan, R. S. A.; Ali, W.; Kiran, S.; Shah, M. S. D.; Tahir, Z. A. and Habib, M. (2018): Rapid detection of infectious bursal disease by loop-mediated isothermal amplification for field analysis. *Iran Journal of Veterinary Research*, 19: 101-107.
20. Khan, RSA; Sajid, S; Habib, M; Ali, W; Shah, MSD and Sarfraz, M (2017): History of Gumboro (Infectious bursal disease) in Pakistan. *Saudi Pharmaceutical Journal*, 25: 453-459.
21. Kumar S, Stecher G. and Tamura K. (2016)“MEGA7: Molecular Evolutionary Genetics Analysis version 7.0 for bigger datasets,” *Molecular Biology and Evolution*, 33:1870-1874.
22. Liu A, Li H, Qi X, Wang Q, Yang B, Wu T, Yan N, Li Y, Pan Q, Gao Y, Gao L, Liu C, Zhang Y, Cui H, Li K, Wang Y and Wang X (2019): Macrophage Migration Inhibitory Factor Triggers Inflammatory Responses During Very Virulent Infectious Bursal Disease Virus Infection. *Frontiers in Microbiology*, 10:2225.
23. Mansour, SM; Ali, H; Chase, CC and Cepica, A (2015): Loop-mediated isothermal amplification for diagnosis of 18 World Organization for Animal Health (OIE) notifiable viral diseases of ruminants, swine and poultry. *Animal Health Research Reviews*, 16: 89-106.
24. Mazengia. H. (2012): Review on major viral diseases of chickens reported in Ethiopia. *Journal of Infectious Diseases and Immunity*, 4:1-9.
25. Meng-Shiou Lee, Yi-Chiu Lin, Guan-Hua Lai, Su-Yaun Lai, Hsi-Jien Chen and Min-Ying Wang. (2011): One-step reverse-transcription loop-mediated isothermal amplification for detection of infectious bursal disease virus. *The Canadian Journal of Veterinary Research*, 75:122–127.
26. Mertens, J.; Casado, S.; Mata, C.P.; Hernando-Perez, M.; de Pablo, P.J.; Carrascosa, J.L. and Castón, J.R (2015): A protein with simultaneous capsid scaffolding and dsRNA binding activities enhances the birnavirus capsid mechanical stability. *Scientific Reports*, 5:13486.
27. Minalu T., Tewodros F. and Bemrew A. (2015): Infectious Bursal Disease (Gumboro) in Chickens. *British Journal of poultry Science*, 4: 22-28.
28. Morla, S., Deka, P. and Kuma, S. (2016): Isolation of novel variants of infectious bursal disease virus from different outbreaks in Northeast India. *Microbial Pathogenesis*, 93:131-136.
29. Moyo, S. and Swanepoel, F. J. C. (2010): “Multifunctionality of livestock in developing communities” in *The Role of Livestock in Developing Communities: Enhancing Multifunctionality*, Copublished by The Technical Centre for Agricultural and Rural Cooperation (CTA) and University of the Free State.
30. Mutinda W. U, L. W. Njagi, P. N. Nyaga, L. C. Bebora, P. G. Mbuthia, D. Kemboi, J. W. K. Githinji, and A. Muriuki (2015): Isolation of Infectious Bursal Disease Virus Using Indigenous Chicken Embryos in Kenya. *International Scholarly Research Notices*. <http://dx.doi.org/10.1155/2015/464376>
31. Mutinda WU, PN Nyaga, PG Mbuthia, LC Bebora and G Muchemi, (2014): Risk factors associated with infectious bursal disease vaccination failures in broiler farms in Kenya. *Tropical Animal Health and Production*, 46: 603–608.
32. Nafi’u Awal, Mohd Hair-Bejo, Siti Suri Arshad, Abdul Rahman Omar, and Aini Ideris (2017): Adaptation and Molecular Characterization of Two Malaysian Very Virulent Infectious Bursal Disease Virus Isolates Adapted in BGM 70 Cell Line. *Advances in Virology*,
33. Neven Ramzy, Shahera Abdel-fattah and Abdel-dayem M. (2015): Prevalence and Molecular

- characterization of Gumboro virus in chicken farms in Somalia. *Assiut Veterinary Medicine Journal*, 61:152-159.
34. Nurulfiza, M. Hair-Bejo, Ar. Omar and I. Aini (2017): Molecular characterization of recent infectious bursal disease virus isolates from Malaysia. *Acta Virologica*, 50: 45–51.
 35. OIE (2016): Office of International des Epizootics. Chapter 2.3.12. *Manual of Diagnostic Tests and Vaccines for Terrestrial Animals, Infectious Bursal Disease (Gumboro disease)*
 36. Rai Shafqat Ali Khan, Habib M, Muhammad Salah Ud and Din Shah (2017): Molecular characterization of infectious bursal disease virus from commercial poultry in Pakistan. *Matrix Science Medica*, 1: 1-6.
 37. Rekha, K., Sivasubramanian, C., Chung, I. and Thiruvengadam, M. (2014): Growth and replication of infectious bursal disease virus in the DF-1 cell line and chicken embryo fibroblasts. *Biomedical Research International*, 6. <http://dx.doi.org/10.1155/2014/494835>
 38. Sali K. (2019): Overview of methods used in the diagnosis of infectious bursal disease. *Veterinary Medicine Open Journal*, 4: 9-17.
 39. Samson Terefe (2018): Infectious Bursal Disease: An Important Challenge in Transforming the Ethiopian Poultry Sector. *Greener Journal of Agricultural Sciences*, 8:277-285.
 40. Shapiro, B.I., Gebru, G., Desta, S., Negassa, A., Nigussie, K., Aboset, G. and Mechal, H (2015): Ethiopia livestock master plan. ILRI Project Report. Nairobi, Kenya: International Livestock Research Institute (ILRI).
 41. Shekaro A (2016): Infectious bursal disease outbreak in fifteen weeks old pullets in Kaduna, Nigeria. *Journal of Animal Production Advances*, 5: 636–644.
 42. Singh J, Banga HS, Brar RS, Singh ND, Sodhi S and Leishangthem GD (2015) Histopathological and immunohistochemical diagnosis of infectious bursal disease in poultry birds. *Veterinary World*, 8: 1331-1339.
 43. Surabhi Rani and Sachin Kumar (2015): Evaluation of infectious bursal disease virus stability at different conditions of temperature and pH. *Biologicals*, 1-4. doi.org/10.1016/j.biologicals.2015.07.005
 44. Swati Sachan, Kuldeep Dhama, Shyma K. Latheef, Hari Abdul Samad, Asok Kumar Mariappan, Palanivelu Munuswami, Rajendra Singh, Karam Pal Singh, Yashpal Singh Malik and Raj Kumar Singh (2019): Immunomodulatory Potential of *Tinosporacordifolia* and CpG ODN (TLR21 Agonist) against the Very Virulent, Infectious Bursal Disease Virus in SPF Chicks, 7:106. [doi:10.3390/vaccines7030106](https://doi.org/10.3390/vaccines7030106).
 45. Tomas G, Hernández M, Marandino A, Hernández D, Techera C, Grecco S, Panzera Y and Pérez R. (2015): Genome sequence of a distinct infectious bursal disease virus. *American society for microbiology*, 3:01061-15. [doi:10.1128/genomeA.01061-15](https://doi.org/10.1128/genomeA.01061-15).
 46. Tsegaye K and Mersha C (2014): Review on the incidence and pathology of infectious bursal disease. *British journal of Poultry Science*, 3: 68–77.
 47. Wahome MW, LWNjagi, PN Nyaga, PGMbuthia, LCBebora and MO Bwana (2017): Occurrence of antibodies to infectious bursal disease virus in non-vaccinated indigenous chicken, ducks and turkeys in Kenya. *International Journal of Veterinary Science*, 6: 159-162.
 48. Y Cao, H. Rashid, Ch. Xue, T. Islam and R. Islam (2013): Risk factors associated with Infectious Bursal Disease in commercial chickens in Bangladesh. *Preventive veterinary Medicine*, 111:181-185.
 49. Yamazaki K, Hideyuki Ohta, Toru Kawai, Tsuyoshi Yamaguchi, Takeshi O and Kozo Takase (2016): Characterization of variant infectious bursal disease virus from a broiler farm in Japan using immunized sentinel chickens. *The Journal of Veterinary Medical Science*, 79: 175–183.
 50. Yao Qin and Shijun J. Zheng (2017): Infectious Bursal Disease Virus-Hist Interactions: Multifunctional viral proteins that perform multiple and differing jobs. *International Journal of Molecular Sciences*, 18:161.
 51. Zegeye, S., Yisehak Tsegaye, Haftey Abrah and Nesibu Awol (2015): Sero-prevalence of infectious bursal disease in backyard chickens around Mekelle, Northern Ethiopia. *African Journal of Biotechnology*, 14:434-437.
 52. Zhao Y, Aarnink AJ, Dijkman R, Fabri T, de Jong MC and Groot Koerkamp PW (2012): Effects of temperature, relative humidity, absolute humidity, and evaporation potential on survival of airborne Gumboro vaccine virus. *Applied and Environmental Microbiology*, 78:1048-1054.