

Toxicity effect of vincristine on mice fetus cerebellumSajjad Hejazi¹, Sina Yaghoubi², Mohamadreza Delghandi² (Corresponding author)

1 - Department of anatomy, Faculty of Veterinary Medicine, Tabriz branch, Islamic Azad University, Tabriz, Iran

2 - Graduated of veterinary medicine, Tabriz branch, Islamic Azad University, Tabriz, Iran

Sajjad.hejazi@yahoo.comcorresponding author: dr.mohamadreza.delghandi@gmail.com

Abstract: Vincristine Alkaloid originates from *Vinca rosea* and its mechanism includes the depolarization of microtubules that take part in the process of mitotic divisions (17,2). This drug stops the chain of cell mitotic so that its usage in the halting of divisions in malignant cancers with high proliferation has been suggested (2,17). Cerebellum, with respect to the formation and appearance of fetus, is originated from metencephalon. The shape of cerebellar neurons and the order of their interstitial space during their development in central nervous system are the same in all vertebrates and abnormal growth of this area causes disturbances in the movement of the given animals.

[Hejazi S, Yaghoubi S, Delghandi MR. **Toxicity effect of vincristine on mice fetus cerebellum.** *Life Sci J* 2013;10(6s):287-291] (ISSN:1097-8135). <http://www.lifesciencesite.com>. 44

Key Words: Vincristine, Mice, fetus, cerebellum

Introduction

In the previous studies, it has been mentioned that the initial appearance of cerebellum is in the form of a mass which is traceable during the pregnancy. Days of 14-17, and the initial shape of cerebellum is recognizable from the 17th day of pregnancy onward and it is in a foliated shape (3). In a study on the development of mice fetus cerebellum it has been observed that X ray and drugs with anti-mitotic activity effects (cytotoxics) have destructive impacts on the regulation (uniformity) of cell development, migration, and the segregation of 3-layer segment of cerebellar cortex (10). In another study which was on the migration of neural tectal cells, followings were reported. When mice were poisoned with the vincristine during the pregnancy period, this drug caused disturbance in chin cephalic and optic cup, and condition of non-growth to asymmetrical-growth were also observable (16). Moreover, damage to Purkinje cells has some relationship with most of illnesses which appear after the maturity period like: spasm, epilepsy, Huntington which are totally suggested as the "cerebellar cognitive affective" syndrome. Such a syndrome is accompanied with the visual and oral Insufficiency (Signals) signs (14,15).

Studies have shown that 23-85 percent of pregnant mothers who received this drug, occurrence of malformation has been observed in their fetus. Yet, there is not enough information on the pathological effect of this drug on the different structures of the newborn fetus (3). In this study, it has been tried to show the placental blood barrier transfer of this drug, and its known cytotoxicity effect, the probable amount of vincristine damage to the formation of cerebellum in newborn fetus.

Materials and Methodology:

In this study, male and female mice with Swiss race, and with the weight of 30±3 were selected. Equal numbers of female mouse were put beside the same numbers of male mouse during the proestrus phase from the estrus cycles (during night). The test of vaginal smear was done at 8 a.m. so that the first day of pregnancy was determined by the observation of sperm in smear and by the formation of vaginal plaques. As such, a total number of 20 mouse were pregnant. Then the pregnant mice were assigned in two groups of control (n=10) and treatment (n=10) randomly. With respect to the frequency of pathological occurrence, following the usage of drug during the period of organogenesis (13,5), and the beginning of initial growth of cerebellum in that period, 3 mg/kg of Vincristine was injected to the treatment group on the 10th and 11th days of pregnancy (9,11). Also, the control group were injected by the normal saline during the same days. After the pregnancy days, out of total newborn fetus, 48 ones from control and treatment groups, were selected for the present study randomly. After performing histotechnique and coloring phases, in order to investigate the changes occurred in the cerebellar structure observations were made under the light microscope using hematoxylin-eosin method. Also, in order to investigate the parameters of the obtained data, mean±SEM was selected between the control and treatment groups. For statistical analyses t-test and SPSS software were performed.

Results

External morphological observations from the newborn fetus of treatment group showed meaningful decrease (p<0.001) in weight and size of the skull,

and the growth of the new born fetus compared with

those of the control group (Table 1).

Table 1. Shows the average parameters of external morphological observations after the injection of 2 dose vincristine on the 10th and 15th days of pragnency, each parameter is presented as mean±SEM (n=20).

Treatment Group	Control Group	parameter
04/0 ± *97/0	04/0 ± 63/1	Weight of fetus/Geran
65/0 ± *97/19	51/0 ± 76/24	Length of tallness/mm
11/0 ± *79/2	13/0 ± 77/7	Width of skull/mm
18/0 ± *13/9	26 ± 56/10	Length of skull/mm

*Shows the meaningful difference from control group (p<0.001).

On the basis of microscopic observations from the initial growth of cerebellum in the newborn infants of control group, three-layer cells of cerebellar cortex were visible and distinguishable from each other. cerebullem was in foliated shape initially, and the development of pia matter around the cerebellum was observable.

In treatment group, the layers of molocular cells, purkench and oranulex, compared with those of control group had irregular tissues and seemed distorted so that the cerebullem had no foliated shape, with no initial chins, and it was observable with a completely initial shape (images 1 and 2).

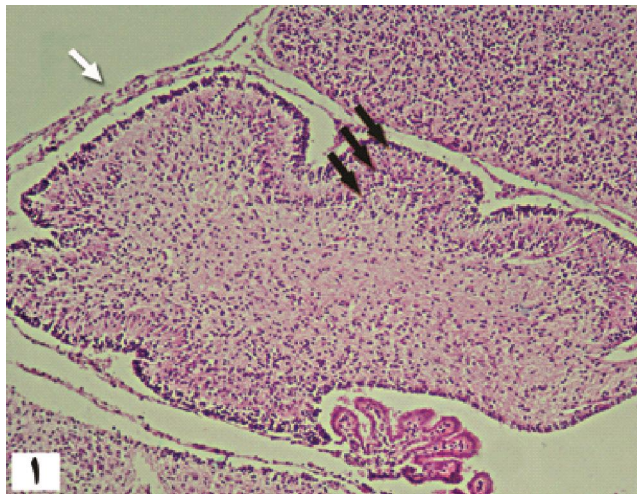
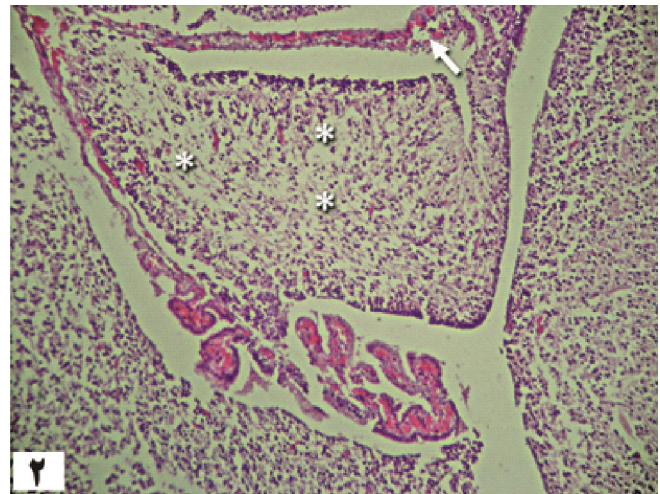


Image 1: shows the microscopic view from the tissue of the cerebellum with three layers (black flash), Meningeal membranes (white Flash), Control group (magnified as 10*H&E).



-Image 2: Shows the microscopic view from the tissue of cerebellum, Meningeal membranes (white Flash), the interstitial space of white material of cerebellum (*), experimental group (magnified as 10*H&E).

By observing the white material of cerebellum in treatment group compared with the normal condition of white material in control group showed a deficiency in tropil tissue that accompanied with the decrease of color-receiving and increase of interstitial space, and decrease of density in neurogilian cells. Also, in experimental group dismyelinateion of nervous cords in white material of cerebellum was observed (images 3,4).

The presence of purkenz cells in experimental groups' cerebellar cortex was rare compared with the density of purkenz cells in control group (images 3,4).

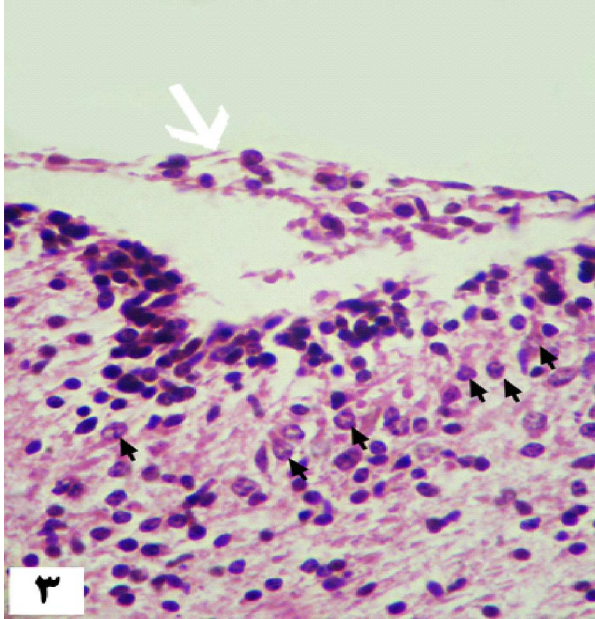


Image 3. Regarding the Meningeal membranes around the cerebellum, the treatment group had a soft tissue plethosis and edematosis compared with the normal condition of the control groups Meningeal membranes(images 3,4).

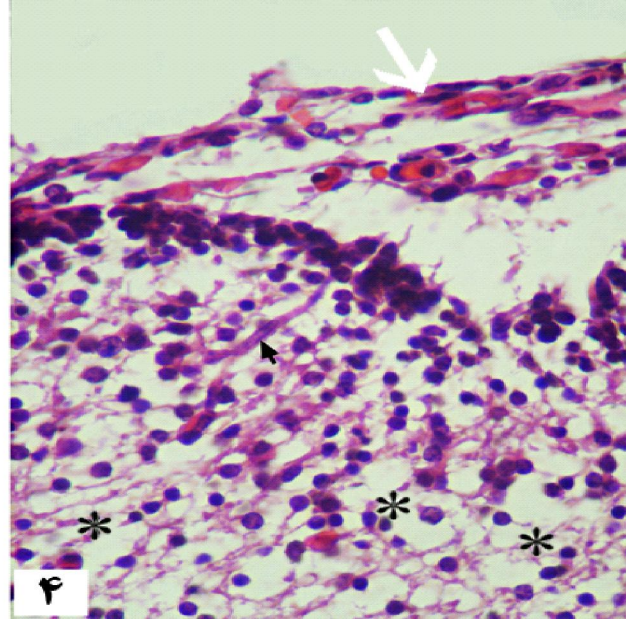
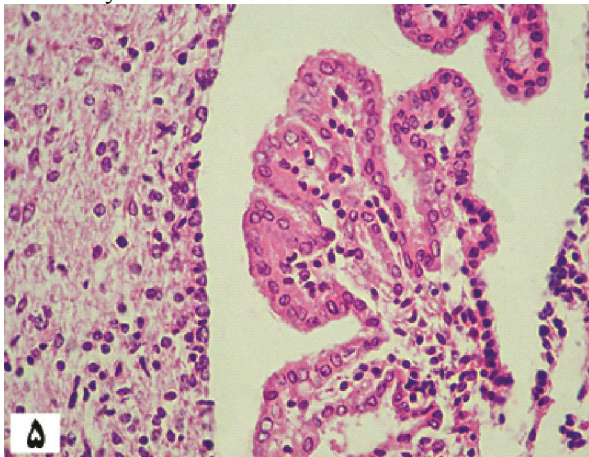


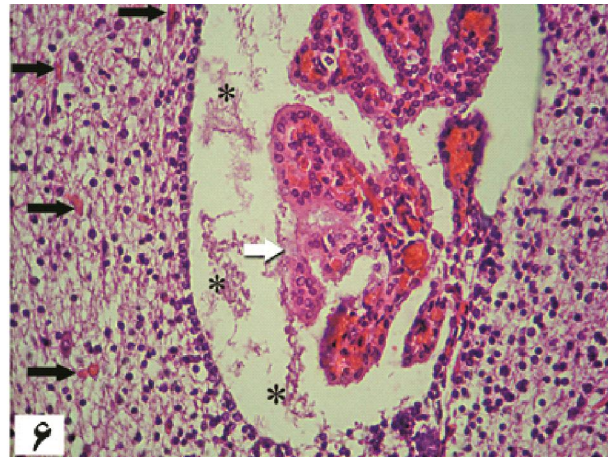
Image 4: Shows microscopic view of cerebellar tissue, Purkinje cell (black flash) Meningeal membranes, interstitial space of white material (*), experimental group (magnified as 40*H&E).

An the observations made from the structure of the fourth ventricle around the cerebellum in control group, the choroidal tissue was developed completely, and the choroidal cells had a normal condition. In experimental group, the structure of the fourth ventricle was plethosis and the choroidal cells, due to the necrotic appearance had lost their uniformity and choroidal tissue was distorted.

Necrotic casts accompanied with fibrin leakage, following the damage to choroidal capillaries of the fourth ventricle space was clearly observable (5,6).



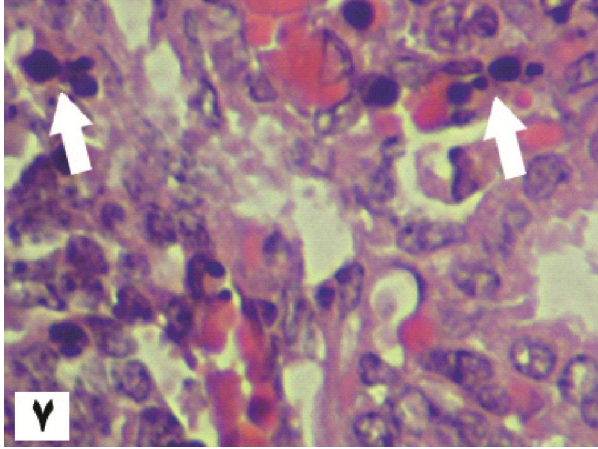
-Image 5: shows a microscopic view of the choroidal plexus of the fourth ventricle in the vicinity of cerebellar tissue, control group (magnified as 40*H&E).



-Image 6: Show a microscopic view of the cerebellar tissue accompanied with the plethosis and appearance of necrotic casts in the ventricle space (*) and the development of blood vessels in cerebellar tissue (black flash), control group (magnified as 40*H&E).

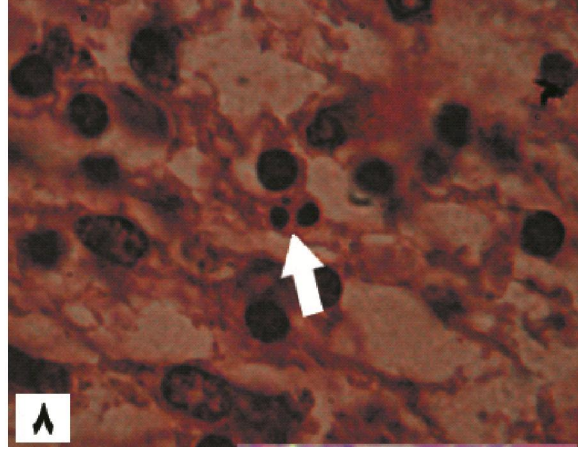
Apoptosis occurrence in cover cells of choroid plexus was one of the other observations made in experimental group compared with those of the control group.

Apoptosis, with an increase in cytoplasmic atypia, condensation, and segmentation of chromatin nuclear, and at last, formation of apoptotic mass was observable



-Image 7. Shows a microscopic view of cover cells of choroid plexus for the ventricle, the segmentation of chromatin nuclear, and the formation of apoptotic mass in cover cells (white arrow), treatment group, (magnified as 160 \times H&E).

-Image 8: Shows a microscopic view of the cover cells of choroid plexus for the ventricle the segmentation of chromatin nuclear, and the formation of apoptotic mass in glial cell of white material of cerebellum, treatment group (magnified as 160 \times H&E).



(image 7). Apoptosis occurrence was also observable sporadically in the neuroglial cells of white material of cerebellum (image 8).

In sum, the changes which were indicators of apoptosis in neural cells of cerebellar cortex were rarely observable.

Discussion and Conclusion

Damages to cerebellar structure are often investigated in the experimental models of pregnancy period, foetal inflammation, brain schemes, and pre-brith studies.

Also, in this study, on the basis of observations made, the descriptions made it obvious that the structure of cerebellum from the organzation period to the end of pregnancy, is pertained to meaningful, irreversible damages (to cerebellum) so that the given damages during the pregnancy period (in utero life) or after the birth may affect fetus physically or cause problems during the maturity period.

In a study performed by Haton and et al (2007) on the development of cerebellum in sheep fetus, with the interference of androtoxin indicated the meaningfulness of the damages to the cerebellar structure in the later period of pregnancy.

In a study, Neki and Sherini (2002) emphasized the malformation event in the process of development in cerebellar cortex.

Also, they asserted that the interference of anti-mitotic activity drugs or X ray in newborn mice creates initial damages to the pia mater of meningeal membranes (10). In addition, in the present study, on the basis of observations made, the damages to newborn fetus of experimental group, due to

vincristine, plethorosis and edema in pia mater around cerebellum were reported.

Kamper and Yuman (1998) studied in the field of neuropathology. They referred to a higher percentage of damage to the structure of cerebellum with a decrease in the number and some times in the size of pruned cells of cerebellum. Also, in the present study, the dense condition of pruned cells in experimental group was emphasized, which is an evidence for the destructive effect of Vincristin on the mitotic activity of pruned cells. Prakash and et al (2007) in a study on mice which was done from the 10th and 12th days of pregnancy (organzation period) showed that cytotoxic cyclocephamide had no significant halting effect on the cover cells of choroid plexus and also it caused apoptosis in the mice brain cells (13). In this study, also, it has been shown that Vincristine had effects on the cover cells of choroid tissue in experimental group with the segmentation of chromatin nuclear apoptosis and its effect on the cells of white material of cerebellum with the occurrence of apoptosis was reported.

Conclusion

On the basis of results obtained from this study and findings of the previous studies, it can be concluded that the effects of drugs with anti-mitotic activity (Cytotoxic) includes:

- Haltering the segregation/proliferation of cells in the cerebellar cortex.
- Improving infusion of apupetuz in the coroidi cell girid and the tissue of the cerebellumitself.

In sum, the present study indicated some new events, in line with the proof of infusion mechanism, retardation in the formation of cerebellum in mice fetus, by one of the chemotherapy drugs namely, vincristine, during the intr-urine lives, also, the infusion of apupetuz and the distortion of cell structure were presented.

Reference

- 1- Adamson R.H., Dixon R.L., Ben M., Crews L., Shochet S.B., Rall D.P.,1965, Some pharmacological properties of vincristine, Arch Int. pharmacodyn Ther., 157:299-311.
- 2-American Society of Hospital Pharmacists Technical Assistance Bulletin on Handling Cytotoxic and Hazardous Drugs,1990, Am J. Hosp Pharm., 47: 1033-1049.
- 3- Goffinet A.M., 1983, The embryonic development of the cerebellum in normal & reeler mutant mice, Anat Embryol, 168:73 86.
- 4- Hellmann k., Hutchinson G.E., Henry k., 1987, Reduction of vincristine toxicity by cronassial, Cancer Chemother Pharmacol, 20 (1): 21-25.
- 5- Hodgson E., A Text-Book of Modern Toxicology, 3rd edi, wiley, Newjersey, 2004, 256.
- 6- Hutton L.C, Yan E., Yawnon T., Castillo-Melendez M., Hirst J.J., Walker D.W., 2007, Injury of the developing cerebellum: A brief review of the effect of endotoxin and asphyxial challengen in the late gestation sheep fetus, Cerebellum, 3:1-10.
- 7- Kemper T.L., Bauman M.,1998, Neuropathology of infantile autism, J. Neuropathol Exp Neurol, 57:645-652.
- 8- Kern J.K., 2003, Purkinje cell vulnerability and autism: a possible etiological connection, Brain & Development, 25: 377-382.
- 9- Mc-Elhatton P.R., Principles of teratology, Obstetrics & Gynecology, 1999, 9(3):163-169.
- 10-Necchi D., Scherini E., 2002, The malformation of the cerebellar fissura prima: A tool for studying histogenetic processes, Cerebellum, 1:137-142.
- 11- Noaks D.E., Parkinson T.J., England G.C.W., Arthur G.H., Veterinary Reproduction and Obstetrics, Sanders, Philadelphia, 2001, 808-809.
- 12-Noden D., Lahunta A., 1985, The Embryology of Domestic Animals, Wilkins, 323-326.
- 13- Parkash R., Gajendra S., Sukhmahendra S., 2007, Cyclophamide induced non-canalization of cerebral aqueduct resulting in hydrocephalus in mice, Neuroanatomy, 6: 1-5.
- 14- Sarna J.R., Hawkes R., 2003, Patterned purkinje cell death in the cerebellum, Prog Neurobiol, 70(6): 473-507.
- 15- Schmahmann J.D, Sherman J.C.,1998, The cerebellar cognitive affective syndrome, Brain, 121 (4): 561-579.
- 16- Svoboda k.k., O'Shea K.S., 1983, Optic vesicle defects induced by vincristine sulfate: An in vivo and in vitro study in the mouse embryo, [Teratology](#), 29(2):223-239.
- 17- Ungthavorn S., Joneja M., 2005, Effects of teratogenic doses of vincristine on mitotic cells in the fetuses of DBA mice, American Journal of Anatomy3: 291 – 297.

3/17/2013