

The Role of Beta Catenin and Platelet Derived Growth Factor Antibodies in Head and Neck Intermediate Grade Soft Tissue Tumors

Amani N. Abd El-Latif¹ and Ibrahim M. Zeitoun²

¹Oral Pathology Department, Faculty of Dentistry, Pharos University, Alexandria, Egypt

²Maxillofacial and Plastic Surgery, Faculty of Dentistry, Alexandria University, Egypt

Amany.noureldin@pua.edu.eg; We_as@hotmail.com

Abstract: Background: Intermediate soft tissue tumors were included in the new WHO classification of soft tissue tumors. They were addressed as locally aggressive tumors with reports of their recurrence or even malignant transformation. This study was conducted to detect the immunoeexpression of Beta Catenin and Platelet Derived Growth Factor in order to predict their potential for malignant transformation. Methods: Twenty three different intermediate soft tissue tumors were included as well as three recurrent cases diagnosed as fibrosarcoma. All lesions were prepared and were subjected to Beta Catenin and Platelet Derived Growth Factor antibodies. **Results:** From the 26 selected cases, 9 were Juvenile fibromatosis, 5 were haemangiopericytoma. 9 were desmoplastic fibroma 3 of which showed recurrence and were diagnosed as Fibrosarcoma. All cases of juvenile fibromatosis, desmoplastic fibroma and fibrosarcoma, showed positive nuclear reaction to **Beta Catenin antibody**. Cytoplasmic reaction of Platelet Derived Growth Factor antibody were observed in 6 cases of juvenile fibromatosis and 5 cases of desmoplastic fibroma as well as the 3 cases that showed recurrence in the form of fibrosarcoma .Conclusion: Intermediate tumors have a benign clinical course, but their clinical behavior is unpredictable.

[Amani N. Abd El-Latif and Ibrahim M. Zeitoun. **The Role of Beta Catenin and Platelet Derived Growth Factor Antibodies in Head and Neck Intermediate Grade Soft Tissue Tumors.** *Life Sci J* 2012;9(4):593-596] (ISSN:1097-8135). <http://www.lifesciencesite.com>. 90

Keyword: Intermediate soft tissue tumors, Beta Catenin, Platelet Derived Growth Factor

1. Introduction

The WHO has a new classification of soft tissue tumors that was introduced in late 2002. As part of this new WHO classification, the Working Group has focused on the definition and the biological potential of lesions, that were addressed as 'intermediate malignancy' or 'borderline malignant potential.' With this goal in mind, they recommended to divide soft tissue tumors into the following four categories: benign, intermediate (locally aggressive), intermediate (rarely metastasizing) and malignant [1]. The Intermediate (locally aggressive) and Intermediate (rarely metastasizing) tumors often recur locally and are associated with an infiltrative and locally destructive growth pattern [2].

β -Catenin is a multifunctional protein, which plays a very important role in cell adhesion and it is localized to the adherence junction on the cell membrane and free cytoplasmic . Mutation of the β -catenin gene results in its stabilization and a significant increase in this protein within the cell. Mutations of β -catenin have been identified in various cancers such as colon cancer and more recently, in soft-tissue tumors [3]. The expression of PDGF and their receptors was demonstrated in a broad spectrum of human cancers [4].

Recent studies have mentioned that PDGF is also expressed in gliomas and sarcomas, which derive from cell types that are normally responsive to PDGF.

Furthermore, it was mentioned that the increased expression of PDGF correlates with the degree of malignancy [4, 5].

The aim of this research is to study the clinical and pathological features of intermediate soft tissue tumors and to investigate whether β -Catenin and Platelet derived growth factor antibodies have a role in finding the liability of malignant transformation of these intermediate tumors.

2. Materials and Methods

Materials were obtained from patients who had undergone surgical excision of their tumors at Maxillofacial Department, Faculty of Dentistry, Alexandria University, Egypt, during the years 2010 through 2012.

A portion of the tumor was used for research after informed consent was obtained .All specimens were fixed in 10% formalin, embedded in paraffin, stained with haematoxylin and eosin for diagnosis.

For immunohistochemical analysis, all sections were cut 5 μ m, embedded in superfrost plus slides. All sections undergo deparaffinization. Antigen retrieval was performed in a microwave oven using 10mM citrate buffer. Endogenous peroxidase activity was blocked with 0.03% hydrogen peroxide containing sodium azide. Slides were incubated with non-immune serum for 30 minutes and were then incubated with the primary antibody for overnight in a moist chamber,

The following antibodies, manufactured by Neo Markers for Lab Vision Corporation (Fermont.CA94538, USA) were used according to manufacturers' recommendations:

- i- Catenin Beta Ab-1 (cat #RB-090-R7)
- ii- Platelet Derived Growth Factor PDGFR (cat#RB-090-R7)

Positive and negative controls as well as oral fibroma that served as an endogenous control group were used. Biotinylated Rabbit anti-Mouse (1:200 w/ 10% NRS) were incubated for 30 min. Slides were rinsed in PBS 3 X 5 min. each. Followed by the application of conjugated HRP Streptavidin (1:1000) incubate to 30 min. Brown color was developed using DAP working solution for 5 min, counter stained with haematoxylin for 15min, washed, dehydrated and mounted.

Cellular localization for Catenin Beta was nuclear and cytoplasmic, while for PDGF was cytoplasmic only.

Nuclear and cytoplasmic immunostaining was determined semi quantitatively.

3. Results

Twenty six selected cases of soft tissue intermediate tumors were collected from head and neck region. Female to male ratio was 1:1.625 with average age 16.5.

The selected cases were diagnosed as follow: nine were Juvenile fibromatosis, five haemangiopericytoma, nine desmoplastic fibroma , three of which showed recurrence and were diagnosed as Fibrosarcoma (3 cases).

Nuclear localization of Beta Catenin antibody was found in almost all the cases with different intensity; All cases of juvenile fibromatosis, desmoplastic fibroma and fibrosarcoma (Figs. 1-3)

Cases of haemangiopericytoma and the endogenous control (intraoral fibroma) showed no reaction.

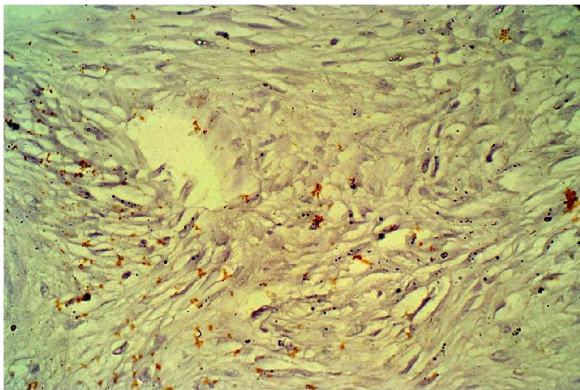


Figure 1: Desmoplastic fibroma with +ve nuclear [beta]-Catenin antibody (X400)

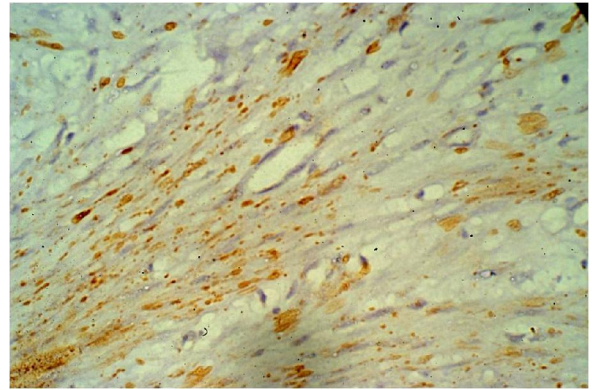


Figure 2: Photo microgram of desmoplastic fibroma with +ve immunohistochemical nuclear stain (β -Catenin x400)

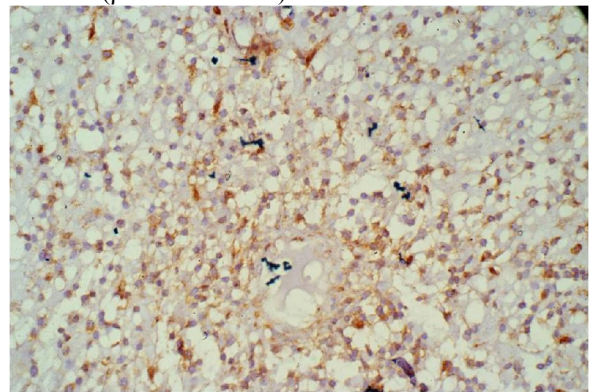


Figure 3: Photo microgram of desmoplastic fibroma with +ve nuclear immunohistochemical stain (β -Catenin x200)

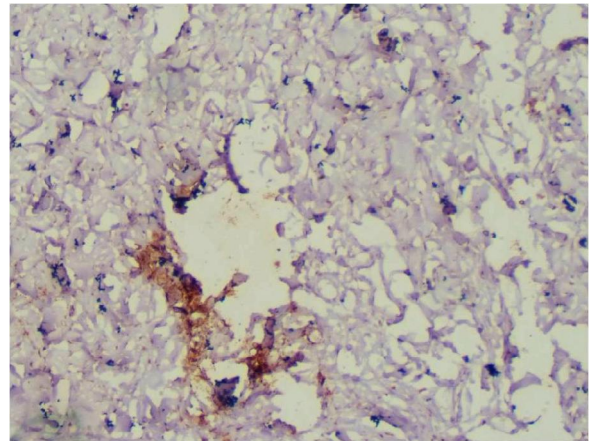


Figure 4: Photo microgram of desmoplastic fibroma with +ve immunohistochemical cytoplasmic & cell membrane stain (PDGFx400)

Cytoplasmic reaction of PDGF were observed in 5 desmoplastic fibroma (Fig 4) including the 3 cases that showed recurrence, cases of fibrosarcoma, and 6 cases of juvenile fibromatosis. (Fig 5)

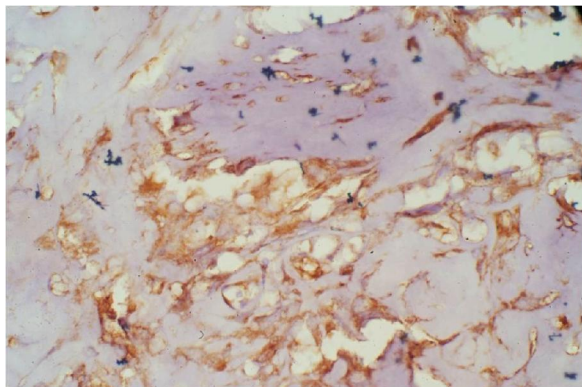


Figure 5: Photo microgram of desmoplastic fibroma with +ve immunohistochemical cytoplasmic & cell membrane stain (PDGFx400)

4. Discussion

On the basis of the microscopic findings it is not always easy to draw a presumptive line dividing what we call intermediate tumors from what we call Grade I fibrosarcoma. This distinction can, in theory be reasonably precise, but considerable possibilities of error must be taken into consideration.

Immunohistochemistry (IHC) is presently the most important adjunct tool in the evaluation of soft tissue tumors because of its practicability and relatively low cost [6]. Furthermore, a small group of soft tissue tumors remains unclassified despite extensive ancillary studies except with IHC [4].

This survey was performed on soft-tissue tumors to find out whether nuclear expression of β -Catenin, as determined by immunohistochemical staining would be relatively specific to and sensitive for tumors in this class.

Our results showed the absence of nuclear localization of β -Catenin in normal fibroblast. This was in accordance with Kim *et al.* [7] who reported a cytoplasmic distribution of β -catenin in fibroblasts without significant amounts at the cell surface, and no nuclear accumulation of β -catenin in regular fibroblasts.

The five cases of haemangiopericytoma showed no immunohistochemical reaction to β -Catenin. Studies conducted by other authors [8] recommend the use of other antibodies panel to distinguish endometrial stromal sarcomas from tumors with a predominant hemangiopericytomatous growth pattern.

On the other hand, high-level nuclear expression of β -Catenin was seen desmoid-type fibromatosis, Juvenile fibromatosis and fibrosarcoma. The findings presented in this study substantiate the significance of β -catenin for soft tissue intermediate tumors and sarcomas as shown by the large nuclear accumulation

which accentuate its role as an oncoprotein. This was in accordance with Kuhnen *et al.* [9] and Al-Daraji *et al.* [6]. In the contrary, other studies have mentioned that nuclear expression of β -Catenin was seen in a very restricted subset of mesenchymal tumors [10, 11].

The role of β -Catenin as an oncoprotein has been analyzed so far in a number of epithelial tumors; an increased expression was also shown in aggressive fibromatosis as a representative of mesenchymal tumors [12, 13].

The present study demonstrate the cytoplasmic accumulation of PDGF antibody in 5 cases of desmoplastic fibroma including the 3 cases that showed recurrence, cases of fibrosarcoma, and 6 cases of juvenile fibromatosis.

It is well known that tumor cells assign neighboring blood vessels to support their own blood supply for oxygen and nutrients and finally for intravasation (to enter into the blood vessels) and extravasation (metastatic spread) through promoting pathologic neovascularization/angiogenesis [14]. This event is potentiated by tumor cells through the production of diffusible angiogenic factors [15].

The expression of PDGF and their receptors was demonstrated in a broad spectrum of human cancers [16]. Furthermore, studies have mentioned that PDGF is also expressed in gliomas and sarcomas, Moreover it was suggested that the increased expression of PDGF correlates with the degree of malignancy [3,4].

Conclusion

On the whole, intermediate tumors have a benign clinical course, but the clinical behavior is unpredictable and the relationship between morphology and clinical behavior is poor.

In our opinion, it would therefore be more honest and practical for therapeutic purposes to consider desmoplastic fibroma and Grade I fibrosarcoma under the same heading, that is as well-differentiated fibrous tumors having very slow but progressive growth and recurring locally when incompletely removed.

Complete surgical resection is commonly accepted as a treatment of choice. Optimal adjuvant treatment for patient at high risk of recurrence or metastases is not known. Therefore, a close long-term follow-up has to be recommended even after radical excision.

Competing Interests

There is no competing interests'.

Author(s) Contribution:**Am. N.:**

Participated in the study design, collection of the background references. Photomicrography of the immunohistochemical results, interpreting and displaying the results of the study, writing the discussion of the results and alignment of the references.

Ib.M.:

Participated in selecting study cases, follow up of these cases, interpreting and displaying the results of the study, writing the discussion of the results.

Corresponding authors**Amani Nour El-Din Abd El-Latif**

Pharos university, Faculty of Dentistry, Mahmoudia ,Smouha.Alexandria , Egypt

E mail: amany.nourelidin@pua.edu.eg

References

- 1- Fletcher CDM, Sundaram M, Rydholm A, Coindre JM, Singer S. Soft tissue tumours: Epidemiology, clinical features, histopathological typing and grading. *WHO*; 2002:9-18.
- 2- **Fletcher CD**: The evolving classification of soft tissue tumours: an update based on the new WHO classification. *Histopathology* 2006. 48:3-12.
- 3- **Shiratsuchi H, Nakashima T, Hirakawa N, Toh S, Nakagawa T, Saito T**, Tsuneyoshi M, Komune S. beta-Catenin nuclear accumulation in head and neck mucoepidermoidcarcinoma: its role in cyclin D1 over expression and tumor progression. *Head Neck* 2007. 29:577-584.
- 4- Raica M, Cimpean AM: Platelet-derived growth factor (PDGF)/PDGF receptors (PDGFR) axis as target for antitumor and antiangiogenic therapy. *Pharmaceuticals* 2010. 3:572-599.
- 5- Thomas K, Andrej V, Sveinung W, Eivind S, Roy M, Lill-Tove B, Tom D: Fibroblast growth factor 2 orchestrates angiogenic networking in non-GIST STS patients. *Kilvaer et al. Journal of Translational Medicine* 2011, 9:104.
- 6- Al-Daraji W, Husain E, Zelger BG, Zelger B: A practical and comprehensive immunohistochemical approach to the diagnosis of superficial soft tissue tumors. *Int J Clin Exp Pathol.*, 2009. 2:119-131.
- 7- Kim K, Daniels KJ, Hay ED: Tissue-specific

- expression of β -catenin in normal mesenchyme and uveal melanomas and its effect on invasiveness. *Exp Cell Res.*, 1998. 245:79-90.
- 8- Bhargava R, Shia J, Hummer AJ, Thaler HT, Tornos C, Soslow RA: Distinction of endometrial stromal sarcomas from 'hemangiopericytomatous' tumors using a panel of immunohistochemical stains. *Mod Pathol.*, 2005. 18:40-47.
 - 9- **Kuhnen C, Herter P, Müller O, Muehlberger T, Krause L, Homann H, Steinau HU, Müller KM**: β -Catenin in soft tissue sarcomas: Expression is related to proliferative activity in high-grade sarcomas. *Mod Pathol.*, 2000.13:1005-1013
 - 10- **Ng TL, Gown AM, Barry TS, Cheang MCU, Chan AKW, Turbin DA, Hsu FD, West RB, Nielsen TO**: Nuclear beta-catenin in mesenchymal tumors. *Mod Pathol.*, 2005. 18:68-74.
 - 11- Saito T, Oda Y, Kawaguchi K, Tanaka K, Matsuda S, Tamiya S, Iwamoto Y, Tsuneyoshi M: Possible association between higher beta-catenin mRNA expression and mutated beta-catenin in sporadic desmoid tumors: real-time semiquantitative assay by TaqMan polymerase chain reaction. *Lab Invest.*, 2002. 82:97-103.
 - 12- Li C, Bapat B, Alman BA: Adenomatous polyposis coli gene mutation alters proliferation through its β -catenin-regulatory function in aggressive fibromatosis (desmoid tumor). *Am J Pathol.*, 1998. 153:709-714.
 - 13- Alman BA, Li C, Pajerski ME, Diaz-Cano S, Wolfe HJ: Increased β -catenin protein and somatic APC mutations in sporadic aggressive fibromatoses (desmoid tumors). *Am J Pathol.*, 1997. 151:329-334.
 - 14- Murukesh N, Five C, Jayson GC: Biomarkers of angiogenesis and their role in the development of VEGF inhibitors. *Br J Cancer* 2010. 102:8-18.
 - 15- Ferrara N: Role of vascular endothelial growth factor in regulation of physiological angiogenesis. *Am J Physiol Cell Physiol.*, 2001. 280:1358-1366.
 - 16- Li C, Shintani S, Terakado N, Klosek SK, Ishikawa T, Nakashiro K, Hamakawa H: Microvessel density and expression of vascular endothelial growth factor, basic fibroblast growth factor, and platelet-derived growth factor in oral squamous cell carcinoma. *Int J Oral Maxillofac Surg.*, 2005. 34:559-563.

9/9/2012