

Effect of Exposure to Mercury on Health in Tropical *Macrobrachium Rosenbergii***Hussein A. Kaoud^{*1}, Manal M. Zaki¹, Mona M. Ismail²**¹Department of Veterinary Hygiene and Management, Faculty of Veterinary Medicine, Cairo University, Giza, Egypt.²Department of Fish Diseases and Management, Faculty of Veterinary Medicine, Suez Canal University, Egypt. ka-oud@link.net*

Abstract: The effects of Hg on mortality, resistance and bioconcentration in the tropical giant freshwater *Macrobrachium rosenbergii* were studied. Mortalities of prawns exposed to mercury doses below 100 µg L⁻¹ were significantly lower than those exposed to higher doses. After 96 hours prawns exposed to >400 µg L⁻¹ of mercury had a greater reduction in total haemocyte count and phagocytic activity than those exposed to lower concentrations. Bioconcentration of mercury (Hg) in the gills, hepatopancreas and muscles was variable. Mercury accumulated in gills and hepatopancreas but Hg accumulation in the muscles only increased marginally. *Macrobrachium rosenbergii* manifested histopathological alterations in gills, hepatopancreas and muscles when exposed to different concentrations of mercury.

[Hussein A. Kaoud, Manal M. Zaki, Mona M. Ismail. **Effect of Exposure to Mercury on Health in Tropical *Macrobrachium Rosenbergii***. Life Science Journal. 2011;8(1):154-163] (ISSN:1097-8135). <http://www.lifesciencesite.com>.

Keywords: *Macrobrachium rosenbergii*, mercury, total haemocyte count, phagocytic activity

1. Introduction:

The contamination of fresh water with a wide range of pollutants has become a matter of concern over the last few decades (Voegborlo *et al.*, 1999; Dirilgen, 2001; Vutukuru, 2005). The natural aquatic systems may extensively be contaminated with heavy metals released from domestic, industrial and other man-made activities (Conacher, *et al.*, 1993; Velez and Montoro, 1998). Heavy metal contaminations may have devastating effects on the ecological balance of the recipient environment and a diversity of aquatic organisms (Ashraj, 2005; Vosyliene and Jankaite, 2006; Farombi, *et al.*, 2007).

The toxic effects of heavy metals have been reviewed, including bioaccumulations (Adami *et al.*, 2002; Waqar, 2006). Heavy metals are surrounded with great care and special importance due to their highly toxic effects on fish as they affect survivability, growth and reproduction. The immune system in all living creatures and the immune response come about as protective mechanism to protect the fish from attack by various microorganisms and parasites (Vorkamp *et al.*, 2004; Andreji *et al.*, 2005). Suppression of immune system and immune response may result from action of several pollutants including heavy metals which provide opportunities for the entering of many pathogens.

Mercury (Hg) is one of the most toxic heavy metals in our environment including the lithosphere, hydrosphere, atmosphere and biosphere (Barbosa *et al.*, 2001). So, Hg was the most toxic of all metals in *Penaeus monodon*, followed by Cu, Cd

and Zn and that Cd toxicity was the most rapid (Chen, 1979).

In freshwater prawn, *Macrobrachium malcolmsonii*, both Hg and Cu had inhibitory effects on the functions of the hemocytes but, the difference between the two metals is the time and concentration at which the effects become apparent (Alcivar-Warren *et al.*, 2006). In decapod crustaceans, 3 types of circulating hemocytes are recognized: hyaline, semi-granular and large granular cells (Tsing *et al.*, 1989). They are involved in cellular immune responses that include phagocytosis and constitute the primary method of eliminating microorganisms or foreign particles (Bayne, 1990). In addition to phagocytosis, hemocytes are involved in the process of coagulation and production of melanin via the prophenoloxidase system (Johansson & Söderhäll 1989, Söderhäll *et al.*, 1996). Enzymes for the prophenoloxidase system are present in the granular hemocytes and released as proenzymes upon stimulation by microbial cell components such as 1, 3-glucan or lipopolysaccharide from fungal cell walls, and activated by a serine protease (Söderhäll 1983, Smith *et al.*, 1984, Söderhäll *et al.*, 1996). Several physico-chemical parameters and environmental contaminants have adverse effect on the immune response of crustaceans (Le Moullac & Haffner, 2000). Environmental toxicants have been reported to cause a reduction in hemocyte count in the common shrimp *Crangon crangon* (Smith & Johnston 1992). Moreover, Heavy metals like mercury and cadmium are known to be accumulated

in marine organisms, and cause rapid genetic changes (Nimmo *et al.*, 1978, Nevo *et al.*, 1986).

Histopathological examination has been increasingly recognized as a valuable tool for field assessment of the impact of environmental pollutants on fish (Heath, 1995; Teh *et al.*, 1997). Specific lesions occurring in organs of fish exposed to toxic substances under laboratory conditions help to identify biomarkers of exposure. Many authors have studied the histopathological effects of mercury on fish exposed to water-borne inorganic mercury (inorganic Hg) on liver, kidneys, gills, olfactory epithelium, and spleen (Oliveira-Ribeiro *et al.*, 2002; Samson and Shenker, 2000).

Knowledge of the toxicity of mercury will be helpful to water quality management in fish farms so; this study evaluates the impact of the short-term mercury exposure on survival, resistance, tissue bioconcentration and histopathological alterations in gills, hepatopancreas and muscles in tropical freshwater prawn (*Macrobrachium rosenbergii*).

2. Materials and Methods

Experimental design

Experiments were carried out in Department of Veterinary Hygiene and Management, Faculty of Veterinary Medicine, Cairo University

Fresh water was adjusted with the desired parameters as follow: temperature of 20-28 °C, pH 7-7.8, dissolved oxygen 5-8 mgL⁻¹, salinity 2 ppt, hardness 100-150 ppm Ca(CO)₃, total ammonia less than 10 ppm, nitrate 20 ppm and nitrite 1 ppm according to, New (1995).

A stock mercury solution was prepared as follow: 135.3 mg Hg Cl₂ salt dissolved in a solution composed of 700 mL water plus 1.5 mL concentrated nitric acid and then diluted up to 1000 mL with water (1.00 mL = 100 µg Hg). Seven different concentrations of Hg were then prepared from the stock solutions (10, 50, 100, 200, 300, 400, 500 µgL⁻¹).

Macrobrachium rosenbergii were obtained from commercial farms in Alexandria and Al-Kalubia, Egypt, and acclimated in the laboratory for two days before the experiment was done.

The toxicity tests were conducted according to the standard procedures of FAO (1985). Seven concentrations of Hg (10, 50, 100, 200, 300, 400 and 500 µgL⁻¹) and a negative control were set up. Ten shrimps each of 13.2 to 16.5 g body weight with an average of 14.85±0.15 g were transferred from the holding tanks into the control and experimental tanks. Three trials were carried out for each

concentration. The aquaria were aerated continuously, while the test solution in each tank was changed with the appropriate fresh solution every 24 hrs to maintain the definite concentration of Hg for 96 hrs. Observations for mortality were made twice (10.0 am and 6.0 pm) daily.

Analysis

The 96 hrs LC₅₀ values were calculated using probit analysis according to Finney (1971).

Cell counts

Hemolymph (100 µl) was sampled individually at the beginning of each test and at 96 h post exposure to Hg. It was withdrawn from the ventral sinus of each prawn into a 1 mL sterile syringe containing 0.9 mL anticoagulant solution (trisodium citrate 0.114 M, sodium chloride 0.1 M, pH 7.45, osmolality 490 mOsm kg⁻¹). A drop of the anticoagulant-hemolymph mixture was placed on a hemocytometer to measure total hemocyte count (THC) using an inverted-phase contrast microscope.

Culture of *Lactococcus garvieae*

The bacterial strain *L. garvieae* isolated from diseased *Macrobrachium rosenbergii* after artificial infection was used in this study. The bacterium was cultured on tryptic soya agar (TSA) for 24 h at 28 °C before being transferred to 10 mL of tryptic soya broth (TSB) for 24 h at 28 °C as a stock culture. The stock cultures were centrifuged at 7155 x g for 15 min at 14 °C and then the supernatant fluid removed and the sediment resuspended in a saline solution (0.85 NaCl) and adjusted at 10¹⁰ cfu mL⁻¹ as stock bacterial suspensions for testing.

Phagocytic activity of *M. rosenbergii* to *L. garvieae*

After 96 hrs of Hg exposure in each treatment, prawns were injected in the cephalothorax with 20 µl of the bacteria suspension (10¹⁰ cfu mL⁻¹ in 0.85% NaCl) resulting in 2 x 10⁸ cfu prawn l⁻¹. After injection, the prawns were held in their respective solutions for 3 hours. Hemolymph (200 µl) was collected from the ventral sinus and mixed with 200 µl of sterile anticoagulant containing sodium citrate (0.8 g), EDTA (0.34 g), Tween 80 (10 µl) and distilled water (100 mL with pH of 7.45).

Phagocytic activity was measured using the method described by Weeks-Perkins *et al.*, (1995) where 200 µl of diluted hemolymph sample was mixed with 0.2 mL of 0.1% paraformaldehyde for 30 min at 4 °C to fix the hemocytes. They were then centrifuged at 800x g at 4 °C, washed and resuspended in 0.4 ml of sterile phosphate buffer

solution. The suspension (50 µl) was spread onto a slide glass and air-dried and stained with Diff-Quick stain according to Skipper R and DeStephano (1989). 200 hemocytes were counted using light microscope and the phagocytic rate was estimated as follows:

$$PR = \frac{(\text{phagocytic hemocytes})}{(\text{total hemocytes})} \times 100.$$

Preparation and analysis of tissue samples

Were carried out in two procedures. Procedure A: Each sample was represented by 0.5 gram of tissues dissected from the gills, hepatopancreas, and muscles, then placed in a clean screw-capped tube and digested according to the method described by Finerty *et al.*, (1990).

Procedure B: The measurement of the mercury concentration in examined tissue samples was carried out at minimal temperature for all samples where 0.5 gram macerated tissues was digested according to the technique described by Diaz *et al.*, (1995). 5 ml stannous chloride solution were added to the obtained solutions to reduce mercury to elemental form and then analyzed by using Atomic Absorption Spectrophotometer equipped with mercury hydride system "MHS" "Cold Vapour Technique".

Histopathological examination

Tissue specimens from gills, hepatopancreas and muscles of experimental *M. rosenbergii* were taken and fixed in 15 % buffered neutral formalin. Tissues were processed to obtain five micron thick paraffin sections then stained with hematoxylin and eosin, (H&E) according to the methods described by Bancroft *et al.*, (1996) and examined under light microscope.

Bioconcentration factor (BCF) is the concentration of a particular chemical in a biological tissue per concentration of that chemical in water surrounding that tissue. That is, a dimensionless number representing how much of a chemical is in a tissue relative to how much of that chemical exists in the environment (Chiou, 2002).

$$BCF = \frac{\text{Concentration}_{\text{Organism}}}{\text{Concentration}_{\text{Environment}}}$$

Tissues with BCF greater than 1,000 are considered high, and less than 250 low, with those between classified as moderate.

Statistical analysis

Data were analyzed using Analysis of Variance (ANOVA) and means were separated by the Duncan post-hoc test at a probability level of < 0.05 (SAS, 2000).

3. Results

Mortality

Tropical *Macrobrachium rosenbergii* exposed to Hg had significantly lower THC and Phagocytic activity than the control ones. After 96 hours, mean (±SD) mortality of prawns in control tanks (0 Hg) was 4±2.20 % and significantly lower ($P < 0.05$) than that of prawns in all other treatments as shown in Table 1 and Figure 1-a. 96 h(s) post-exposure, mortality rates of prawns exposed to 10-50 µgL⁻¹ concentrations of mercury were significantly lower ($P < 0.05$) than those exposed to higher concentrations (100 µgL⁻¹ or greater), but were not significantly different from each other ($P < 0.05$). In Table 1 and Figure 1-a, mortality rates of prawns exposed to 100, 200, 300, 400 and 500 µgL⁻¹ of mercury were significantly higher ($P < 0.05$), with means of (±SD) 23 ± 0.70%, 40 ± 0.70%, 43 ± 0.70%, 60 ± 0.20% and 70 ± 0.21%, respectively.

Resistance

Table 1 and Figure 1-b, show the significant reduction ($P < 0.05$), in THC and Phagocytic activity for prawns exposed to 100, 200, 300, 400 and 500 µgL⁻¹ of mercury with means of (±SD) 170±19, 70±7.00; 160±28, 62±7.00; 145±21, 50±2.70; 138±19, 40±0.70 and 132±16, 0 respectively.

Bioconcentration and residues of mercury (Hg) in different tissues of tropical *M. rosenbergii*

Table 2 and Figure 2, show the residues of mercury (Hg) in gills, hepatopancreas and muscle tissues of tropical *M. rosenbergii* which were higher in the hepatopancreas > gills > muscles. The BCF for 96 h(s)-exposure were less than 250 in hepatopancreas, gills and muscles respectively.

Hepatopancreas:

The rate of accumulation of mercury was maximum in hepatopancreas of exposed prawns and no detectable amount of mercury was observed in the hepatopancreas of control prawns as well as in exposed prawns to very low concentration of mercury (10-50 µgL⁻¹). The rate of accumulation increased along with the increasing of mercury concentration reaching 11.12± 0.032 at 400 µgL⁻¹.

Gills:

As with the case of hepatopancreas, mercury could not be traced in the gills of the control prawn as well as in exposed prawns to very low concentration 10 µgL⁻¹, even though the quantity of accumulated mercury was relatively less in the case of gills (9.14± 0.042 at 400 µgL⁻¹) when

compared to hepatopancreas, the pattern of accumulation showed a more or less continuous increasing trend.

Muscles:

The rate of accumulation of mercury in muscle increased along with exposure to increased mercury concentration. The mean quantity of mercury residue at 400 $\mu\text{g L}^{-1}$ was 1.025 ± 0.002 . The rate of accumulation was less as compared with other tissues.

The LC50 of Hg in tropical *M. rosenbergii*

The 96-hour LC₅₀ values of mercury in tropical *M. rosenbergii* were calculated using probit analysis, to be 430 $\mu\text{g L}^{-1}$ (Fig.3).

Histopathological alterations in different tissues of tropical *M. rosenbergii*

Results of the present study revealed that, tropical *M. rosenbergii* manifested histopathological changes in gills, hepatopancreas and muscles.

Exposure to concentration 0.4 mg L^{-1} for 96 hours resulted in profound structural changes as shown in Figures 4, 5 and 6.

Gills showed mild congestion, swelling and edema at low doses of Hg exposure. Severe edema, hyperplasia, at highest doses of intoxication was observed. Moreover, accumulation of hemocytes in the hemocoelic space; swelling of the lamellae; abnormal gill tips; and hyperplastic, necrotic, and clavate-globate lamellae in the gills (Fig.4).

Hepatopancreas showed hemocytic infiltration in the interstitial sinuses, an increased number of hemocytes, thickening and ruptures of the basal laminae, and necrosis of the tubules were observed in the hepatopancreas (Fig.5 a&b).

Muscular tissues showed several histopathological alterations. The pathological findings included degeneration in muscles with infiltration and aggregations of hemocytes between them and focal areas of necrosis. Also, atrophy of muscle bundles, edema, hyaline degeneration and splitting of muscle fibers were seen (Fig.6 a&b).

Table 1: Effect of mercury 96 hrs-exposure on mortality, total hemocyte count (THC) and phagocytosis in tropical freshwater prawns, *Macrobrachium rosenbergii*.

Hg ¹ Conc.	Mortality %	Immune response	
		THC ²	Phagocytic%
0	4±2.20	186±60	91±7.50
0.01	14±1.70	185±36	90±9.78
0.05	14±1.60	179±22*	88±6.00
0.10	23 ± 0.70*	170±19*	70±7.00*
0.2	40 ± 0.70*	160±28 *	62±7.00*
0.3	43 ± 0.70*	145±21*	50±2.70*
0.4	60 ± 0.20*	138±19*	40±0.70*
0.5	70 ± 0.21*	132±16 *	0

¹: Hg²⁺ mg L^{-1} , ²: $\times 10^3 \text{ mL}^{-1}$, *Significant ($P < 0.05$). Values are means± SD (n = 4 prawns in each case).

Table 2. Bioaccumulation of mercury in tissues of tropical freshwater prawns, *Macrobrachium rosenbergii*, exposed to mercury for 96 hours.

Conc. of Hg ¹	Bioaccumulation in tissues ²		
	Gills	Hepatopancreas	Muscles
0	0	0	0
0.01	0.005 ± 0.00	0.002±0.006	0
0.05	0.01 ± 0.009	0.025±0.008	0.001±0.0001
0.10	2.15 ± 0.018	5.03±0.012	0.42±0.013
0.2	5.066 ± 0.021	7.14±0.098	0.52±0.005
0.3	7.28± 0.032	10.06±0.011	0.83±0.31
0.4	9.14± 0.042	11.12± 0.032	1.025± 0.002
0.5	9.00 ± 0.011	11.12 ± 0.022	1.015±0.021

¹: Hg²⁺ mg L^{-1} , ²: Hg²⁺ $\mu\text{g gm}^{-1} = \text{mg kg}^{-1} = \text{ppm}$. Values are means± SD.

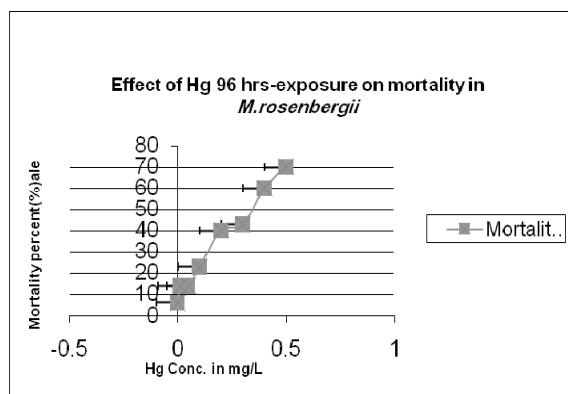


Fig.1-a: mortality rates of prawns exposed to 100, 200, 300, 400 and 500 µg L⁻¹ of mercury were significantly higher (P < 0.05), with means of (±SD) 23 ± 0.70%, 40 ± 0.70%, 43 ± 0.70%, 60 ± 0.20% and 70 ± 0.21%, respectively.

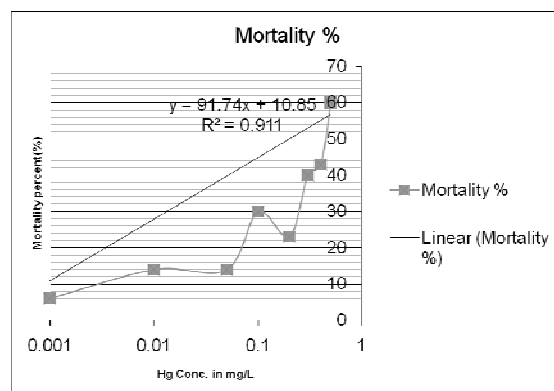


Fig.3: The 96-hour LC₅₀ values of mercury in tropical *M. rosenbergii* were calculated using probit analysis, to be 430 µg L⁻¹.

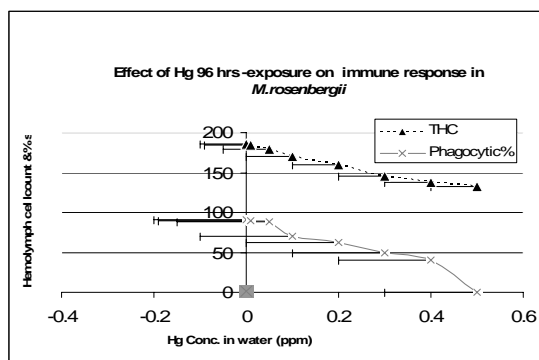


Fig.1-b : the significant reduction (P < 0.05), in THC and Phagocytic activity for prawns exposed to 100, 200, 300, 400 and 500 µg L⁻¹ of mercury with means of (±SD) 170±19, 70±7.00 ; 160±28 , 62±7.00; 145±21, 50±2.70; 138±19, 40±0.70 and 132±16 , 0 respectively.

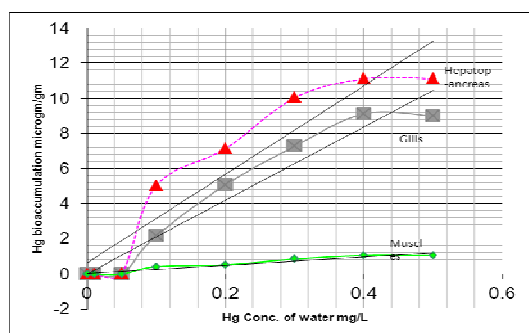


Fig.2: The residues of mercury (Hg) in gills, hepatopancreas and muscle tissues of tropical *M. rosenbergii* which were higher in the hepatopancreas > gills > muscles. The BCF for 96 h(s)-exposure were less than 250 in hepatopancreas, gills and muscles respectively.

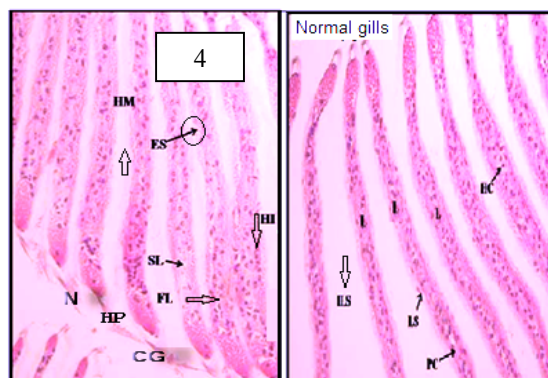


Fig.4 Cross-sections of gill lamellae of *M. rosenbergii* after 96 h of exposure to a control solution and Hg . Control prawn showing normal lamellae (L) with uniform interlamellar spaces (ILS), the lamellar sinus (LS), and pillar cell (PC) and hemocyte (HC) in the lamella. Mercury exposed prawn showing hemocytic infiltration (HI), swollen (SL) and fused (FL) lamellae, enlargement of the lamellar sinuses (ES) and hyper-mucus (HM) in the interlamellar spaces, necrosis (N) and hyperplasia (HP) tip of lamellae. H&E stain, (x200).

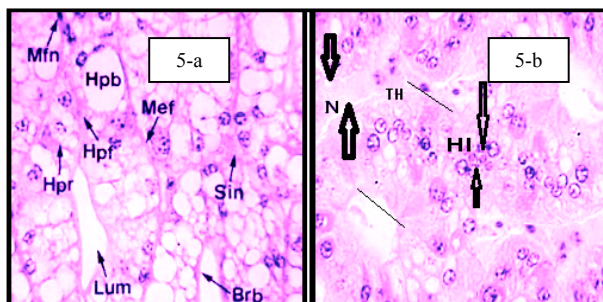


Fig .5-a: Cross sections of hepatopancreatic tubules: normal lumens (Lum), tubule tissues (Hpf: F-cell; Hpb: B-cell; Hpr: R-cell; Mfn: myoepithelial cell nuclei; Mef: myoepithelial layer; Brb: microvillus brush borders) and hemal sinuses (Sin) between tubules. **Fig.5-b:** Cross sections of hepatopancreatic tubules: showed hemocytic infiltration (HI) in the interstitial sinuses, an increased number of hemocytes, thickening (TH) and ruptures of the basal laminae, and necrosis (N) of the tubules (arrowheads). H&E stain, (x200).

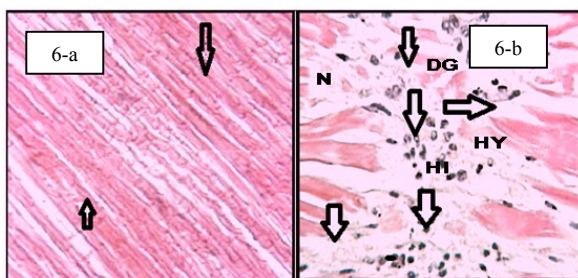


Fig.6-a: Longitudinal sections of muscle tissue Healthy prawn tissue showing normal muscle fibres. **Fig.6-b:** Cross section showing degeneration (DG), focal areas of necrotic musculature (N) infiltrated by hemocytes (HI) (arrowheads). Also, atrophy of muscle bundles, edema, hyaline degeneration (HY) and splitting of muscle fibers were seen. H&E stain, (x200).

4. Discussion:

After 96 h(s) post-exposure, the survival of tropical *M. rosenbergii* exposed to 10-50 μgL^{-1} concentrations of mercury were significantly greater ($P < 0.05$) than those exposed to higher concentrations (100 μgL^{-1} or greater).

Cheng (1979) tested Hg, Cu, Cd and Zn in *Penaeus monodon* and found that, Hg was the most toxic of all metals, followed by Cu, Cd and Zn. In our study in which prawns exposed to 100, 200, 300, 400 and 500 μgL^{-1} of mercury concentrations had

significantly greater reduction in THC and phagocytic activity than prawns exposed to lower concentrations (10 – 50 μgL^{-1}), ($P < 0.05$). Our findings may confirm the results reported by Cheng (1979).

Several scientists have investigated the effects of environmental contaminants on crustacean defense mechanisms. Carolina (2009) studied the effect of Mn on the immune system of marine invertebrates and found that Mn severely suppresses the number of circulating hemocytes in *Nephrops norvegicus* by inducing apoptosis. However, Mn increased the number of circulating hemocytes in *Asterias rubens* and at the same time affected their ability to phagocyte. Circulating hemocytes can be affected by extrinsic factors in several species of decapods crustaceans (Truscott & White 1990, Le Moullac et al. 1998, Le Moullac & Haffner 2000, Cheng & Chen2001).

In freshwater prawn, *Macrobrachium malcolmsonii*, Alcivar-Warren, (2006) reported that both Hg and Cu had inhibitory effects on the functions of the hemocytes, the difference between the two metals being the time and the concentration at which the effects become apparent and suppression of total counts of hemocytes (hemopoiesis) appears to involve metal transport (96 h LC50 for Hg = 0.145 mgL^{-1} when 0.024 mgL^{-1} Hg (1/6th of LC50) was used, the total hemocyte count, percentile phagocytosis and superoxide anion production was significantly lower than the controls.

The immune system in all living creatures and the immune response come about as protective mechanism to react and protect the fish from attack by various microorganisms and parasites (Vorkamp et al., 2004; Andreji et al., 2005). Suppression of immune system and immune response may results from action of several pollutants including heavy metals which provide opportunities for entering of many pathogens.

In the present study the highest bioaccumulation of mercury was observed in the organs mainly implicated in metal intoxication (hepatopancreas). Mercury (Hg) in tissues was high in the hepatopancreas > gills > muscles.

Tropical *M. rosenbergii* manifested histopathological changes in gills, hepatopancreas and muscles. Exposure to concentration 400 μgL^{-1} for 96 hours resulted in profound structural changes as shown in Figures 4, 5 and 6.

Victor et al., (1990) studied the effect of HgCl₂ on *Macrobrachium idae* exposed to 1×10^{-3} mg/L of HgCl₂ and found that there were Hyperplastic gill lamellae engorged with hemocytes as a specific toxic reaction in these prawns, then hemocytes were released into the interlamellar

spaces through necrotic regions and blanketed the entire gill lamellae. Also, Piyan et al (1985) revealed that stage 1 larvae had the lowest threshold lethal concentration (TLC) of mercury, 0.041 ppm Hg, while the post-larvae had a TLC of 0.325 ppm Hg.

Similar results were observed by Mela et al. (2007) and Frias-Espericueta et al., (2008) who studied the effect of three concentrations of Cu (3.512, 1.756 and 0.877 mg L⁻¹) on juvenile *Litopenaeus vannamei* and found that there were severe time- and dose-dependent structural damages, such as necrosis, loss of regular structure and infiltration of hemocytes in the gill tissues, as well as atrophy, necrosis and irregular tubular structure in the hepatopancreas, similar to that reported by Li et al., (2009).

The higher Hg concentration in the hepatopancreas suggested that this organ plays a role in metal storage and/ or in detoxification process by a metal binding component (White and Rainbow 1986). In crustacean, the hepatopancreas is the primary organ responsible of absorption and storage of ingested materials (Vogt et al., 1989; Johnston et al., 1998). Also, this organ is involved in the synthesis of digestive enzymes and the detoxification of xenobiotics (Barker and Gibson, 1979; Icely and Nott, 1992) were apparent as the hepatospleen consider the organ of detoxification, excretion and binding proteins such as metallothionein (MTs). The metal-binding proteins that present in the nuclei of hepatocytes suggested an increase in cell damage (De Smet and Blust, 2001).

Liver of fish is sensitive to environmental contaminants because many contaminants tend to accumulate in the liver and exposing it to a much higher levels than in the environment, or in other organs (Heath 1995). Pandey et al., (1994) described the alterations in liver and intestine of *Liza parsia* exposed to Hg Cl₂ (0.2 mg Hg L⁻¹) for 15 days. Similarly, Oliveira Ribeiro et al. (2002) reported serious injuries in gills and olfactory epithelium of *Salvelinus alpinus* exposed to 0.15 mg Hg L⁻¹.

M. rosenbergii are able to tolerate low levels of mercury pollution but, high levels lead to cellular injury and tissue damage in hepatopancreas. Hg²⁺ disrupted the histostructures of the hepatopancreas, causing decreases in activities of pepsin, trypsin, amylase, and cellulase, which are synthesized in the hepatopancreas, and worst survival rate of the crabs in 0.30 mgL⁻¹ (Zhao et al., 2010).

Mean mercury accumulation in muscles of *M. rosenbergii* at 400 µg L⁻¹ was 1.025 µg g⁻¹ and the maximum permissible limits recommended by

WHO, (1984) is 1µg g⁻¹. The recorded results of mercury concentrations in muscles of *M. rosenbergii* were higher than the permissible limits intended by Spain: Boletín Oficial del Estado (1991), Schumacher and Domingo (1996) in Spain [1 µg g⁻¹], FAO/WHO (1992) [0.5 µg g⁻¹] and Quality Control (E.O.S.Q.C) (1993) [0.1 µg g⁻¹].

Frias-Espericueta et al. (2009) found that the mean contents of Cd, Cu, Pb and Zn of the white shrimp (*Litopenaeus vannamei*) were lower in the muscle than in the corresponding hepatopancreas samples, which is in agreement with most literature on the metal contents in the tissues of different aquatic organisms because the hepatopancreas is the main organ for metal accumulation (Roesijadi and Robinson 1994, Yang et al. 2007).

5. Conclusion:

This study reveals an important precaution for prawn cultivation. Knowledge of the toxicity of mercury will be helpful to water quality management in fish farms with reference to prawn culture since it affected the immune response and cause a reduction in hemocyte count in *Macrobrachium rosenbergii*. Mercury (Hg) caused a decrease in hemocyte-related functions of tropical freshwater shrimp, including hemocyte count and percentile phagocytosis. Caution should be exercised against water source contamination and exposure to industrial pollution. For this reason, the assessment of risk and the safe levels of toxic substances added to any natural environment through human or natural sources, should not neglect the effects on biological systems caused by exposure to minute amounts of toxicants.

Acknowledgements

The authors are grateful to Dr. Sherin Saeid, assistant professor in the Department of Pathology, Faculty of Veterinary Medicine, Cairo University and Dr. Sahar Tawfik, Researcher in the Institute of Animal Health Research, Agricultural Research Centre, Dokki, Giza, for their valuable input and good collaboration during planning and writing of this review.

6. References:

- Adami G. M., Barbieri P., Fabiani M., Piselli S., Predonzani, S., Reisenhofer E., (2002). Levels of cadmium and zinc in hepatopancreas of reared *Mytilus galloprovincialis* from the Gulf of Trieste (Italy). *Chemosphere*, 48 (7), 671 – 677.
- Alcivar-Warren A., Primavera J. H., Leobert D. de la Pena L D., Pettit P. , Xu Z. (2006). Heavy Metals, Pcb's And Pch's In *Penaeus Monodon* Shrimp From The Philippines: Indicators Of Environmental Contaminants Exposure

3. Andreji J., Stranai I., Massanyi P., Valent M., (2005). Concentration of selected metals in muscle of various fish species. *J Environ Sci Health*. 40A:899–912.
4. Ashraj, W., (2005). Accumulation of heavy metals in kidney and heart tissues of *Epinephelus microdon* fish from the Arabian Gulf. *Environ. Monit. Assess.*, 101 (1-3), 311-316.
5. Bancroft J.D, Stevens A., Turner D.R. (1996). *Theory and Practice of Histological Techniques*. 4th Ed. New York, Churchill, Livingstone.
6. Barbosa A.C., Jardim W., Dorea J.G., Fosberg B., Souza J., (2001). Hair mercury speciation as a function of gender, age and body mass index in inhabitants of the Negro River basin, Amazon, Brazil. *Arch Environ Contam Toxicol* 2001; 40: 439–44.
7. Bayne, C. J., (1990). Phagocytosis and non-self recognition in invertebrates. Phagocytosis appears to be an ancient line of defense. *Bioscience* 40:723–731
8. Boletín Oficial del Estado (1991). Además, las distintas editoriales jurídicas (el BOE, Cívitas, Aranzadi o Tecnos, por ejemplo) suelen hacer ediciones reducidas de las principales leyes agrupadas por bloques temáticos, ediciones que resultan muy asequibles y son de fácil manejo.
9. Chen, C.A., (1979). Preliminary report on the Gonadal Development and Induced Breeding of *Penaeus monodon Fabricius*. M.S. Thesis. Institute of Oceanography, National University Taipei, Taiwan
10. Chiou, C.T.,(2002). Bioconcentration of Organic Contaminants, in Partition and Adsorption of Organic Contaminants in Environmental Systems: Hoboken, NJ, John Wiley & Sons, Inc., p. 257.
11. Conacher, H. B., Page, B. D., Ryan, J. J., (1993). Industrial chemical contamination of foods [Review]. *Food Addit. Contam.*, 10 (1), 129-143.
12. DeSmet H., Blust R., (2001). Stress responses and changes in protein metabolism in carp (*Cyprinus carpio*) during cadmium exposure. *Ecotoxicology and Environmental Safety* 48: 255-62.
13. Diaz, V.R., (1995). Preliminary results of acute toxicity tests for mercury and cadmium on Milkfish (*Chanos chanos Forsskal*) juveniles. In: Watson D, Ong KS, Vigers G. (eds). ASEAN Criteria and Monitoring: Advances in Marine Environmental Management and Human Health Protection. Proceedings of the ASEAN-Canada Midterm Technical Review Conference on Marine Science (24-28 October 1994), Singapore. EVS Environment Consultants, Vancouver, and National Science and Technology Board, Singapore.
14. Dirilgen, N., (2001). Accumulation of heavy metals in freshwater organisms: Assessment of toxic interactions. *Turk. J. Chem.*, 25 (3), 173-179.
15. Carolina O., (2009). Immunotoxicology in marine invertebrates: effects of Mn on the immune responses. MD thesis, School of Life Sciences, Heriot-Watt University, Edinburgh, UK.
16. Cheng W., Chen J. C., (2001). Effect of intrinsic and extrinsic factors on the haemocyte profile of the prawn, *Macrobrachium rosenbergii*. *Fish Shell fish Immunol* 11:53–63.
17. Cheng, H.C., (1979). Acute toxicity of heavy metals to some marine prawns. *China Fish. Mon.* 316:3-10. In Chinese with English abstract.
18. Egyptian organization for standardization and quality control (E.O.S.q.c.) (1993): Maximum residue limits for heavy metals in food. Ministry of Industry.No.2360/ 1993. pp.5, Cairo, Egypt.
19. FAO, (1985). Manual of methods in aquatic environment research. Part 4. Bases for selecting biological tests to evaluate marine pollution: FAO fish tech paper 164.
20. FAO/WHO,(1992). Joint Expert Committee on food Additives, WHO Technical ReportseriesNo.505(1972);No.555(1974c);No.683(1982);No751(1987)andNo.776(1989)Evaluation of certain food additives and contaminants, Geneva.
21. Farombi, E. O., Adelowo, O. A., Ajimoko. Y. R., (2007). Biomarkers of oxidative stress and heavy metal levels as indicators of environmental pollution in African Cat fish (*Clarias gariepinus*) from Nigeria ogun river. *Int. J. Environ. Res. Public Health.*, 4 (2), 158-165.
22. Frías-Espéricueta, M.G., J.I. Osuna-López, D. Voltolina, G. López-López, G. Izaguirre-Fierro & M.D. Muy-Rangel. (2008). The metal content of bivalve molluscs of a coastal lagoon of NW Mexico. *Bull. Environ. Contam. Toxicol.*, 80: 90-92.
23. Frías-Espéricueta, M.G., J.I. Osuna-López, D. Voltolina, M.A. Beltrán-Velarde, G. Izaguirre-Fierro, G. López-López, M.D. Muy-Rangel & W. Rubio-Carrasco. (2009). The content of Cd, Cu, Pb and Zn of the white shrimp *Litopenaeus vannamei* of six coastal lagoons of Sinaloa, NW Mexico. *Rev. Biol.Mar. Oceanogr.*, 44: 197-201.
24. Finerty M.W., Madden J.D., Feagly S.E., Grodner R.M., (1990). Effect of environs and seasonality on metal residues in tissues of wild and pond raised Cray fish in Southern Louisiana. *Archives of Environmental Contamination and Toxicology* 19: 49-55.

25. Finney D.J., (1971). Probit Analysis. Cambridge University Press 1971.
26. Gibson R., Barker P. (1979). The decapod hepatopancreas. *Oceanogr. Mar. Biol. Ann. Rev.* 17, 285-346.
27. Heath A.C., (1995). Water pollution and fish physiology. 2nd edn., Lewis Publishers, Boca Raton. pp. 125-140.
28. Icely JD, Nott JA (1992). Digestion and absorption: digestive system and associated organs. In: Microscopic anatomy of invertebrates: Decapod, Crustacea. Vol. 10. F.W. Harrison and A.G. Humes, Eds. Wiley-Liss Inc., N.Y., pp 147-201.
29. Johansson M.W, Söderhäll K., (1989). Cellular immunity in crustaceans and the proPO system. *Parasitol. Today.* 5:171-176.
30. Johnston, J. A., Ward, C. L., Kopito, R. R., (1998). Aggresomes: A cellular response to misfolded proteins. *The Journal of Cell Biology*, 143, 1883-1898.
31. Le Moullac G., Haffner P., (2000). Environmental factors affecting immune response in Crustacea. *Aquaculture* 191: 121-131
32. Le Moullac G., Soyeux C., Saulnier D., Ansquer D., Avarre J.C., Levy P., (1998). Effect of hypoxia stress on the immune response and the resistance to vibriosis of the shrimp *Penaeus stylirostris*. *Fish Shell fish Immunol* 8:621-629
33. Li, X., Cai, W., An, J., Kim, S., Nah, J., Yang, D., Piner, R., Velamakanni A., Jung I., Tutuc, E., Sanjay, K., Banerjee, K., Colombo, L and Ruoff, R. S. (2009). Large-Area Synthesis of High-Quality and Uniform Graphene Films on Copper Foils. *Science*, 324(5932): 1312-1314.
34. Mela M.R., Ventura .F, Carvalho D.F, Pelletier C.E, Ribeiro C.A., (2007). Effects of dietary methyl mercury on liver and kidney histology in the neotropical fish *Hoplias malabaricus*. *Ecotoxicology and Environmental Safety* 68: 426 - 35.
35. Nevo E., Noy R., Lavie B., Beiles A., Muchtar S., (1986). Genetic diversity and resistance to marine pollution. *Biological Journal of the Linnean Society* 29: 139-144.
36. New, M.B., (1995). Status of freshwater prawn farming: a review. *Aquatic Research* 26: 1-54.
37. Nimmo D.R., Rigby R.A., Bahner L.H., Sheppard J.M., (1978). The acute and chronic effects of cadmium on the estuarine mysid, *Mysidopsis bahia*. *Bulletin of environmental Contamination and Toxicology* 19: 80-85.
38. Oliveira-Ribeiro .CA., Belger L., Pelletier E., Rouleau C., (2002). Histopathological evidence of inorganic mercury and methyl mercury toxicity in the arctic charr (*Salvelinus alpinus*). *Environmental Research* 90: 217-225.
39. Pandey A.K., Mohamed M.P., George K.C., (1994). Histopathological alterations in liver and intestine of *Liza parsia* (Hamilton-Buchanan) in response to mercury toxicity. *Journal of Advanced Zoology* 15: 18-24.
40. Piyan B. T., Law A. T., Cheah S. H., (1985). Toxic levels of mercury for sequential larval stages of *Macrobrachium rosenbergii* (de Man). *Aquaculture* Volume 46, Issue 4, 15 . 353-359
44. Roesijadi G., Robinson W.E., (1994). Metal regulation in aquatic animals: mechanisms of uptake, accumulation, and release. In: Malins DC, Ostrander GK (eds). *Aquatic toxicology: molecular, biochemical and cellular perspectives*; pp. 387-420. Lewis Publishers, Boca Raton.
45. SAS Institute, (2000). SAS User's Guide: statistics, SAS Institute, Cary, NC.
46. Schuhmacher M., Domingo J.L., (1996). Concentrations of selected elements in oysters (*Crassostrea angulata*) from the Spanish Coast. *Bulletin of Environmental Contamination and Toxicology*, 56, 106-113.
47. Skipper R., DeStephano D., (1989). Diff-Quik stain set. *J.Histotechnol.*, 12 (4), 303.
48. Smith V.J., Johnston P.A., (1992). Differential haemotoxic effect of PCB congeners in the common shrimp, *Crangon crangon*. *Comp. Biochem. Physiol. C* 101: 641-649.
49. Smith V.J., Söderhäll K., Hamilton M., (1984). 1, 3-glucan induced cellular defense reaction in the shore crab, *Carcinus maenas*. *Comp Biochem Physiol. A.* 77: 636-639.
50. Söderhäll K., (1983). 1, 3-glucan enhancement of protease activity in crayfish hemocyte lysate. *Comp Biochem Physiol B* 74:221-224
51. Söderhäll K., Cerenius L., Johansson M.W., (1996). The prophenoloxidase activating system in invertebrates. In: Söderhäll K, Iwanaga SGR, Vasta GR (eds) *New directions in invertebrate immunology*. SOS Publications. Fair Haven NJ, p 229-253
52. Truscott R., White K.N., (1990). the influence of metal and temperature stress on the immune system of crabs. *Funct Ecol* 4:455-461
53. Tsing A., Arcier J.M., Bréhélin M., (1989). Haemocytes of penaeids and palaemonid shrimps: morphology, cytochemistry and hemograms. *J Invertebr Pathol* 53:64-77
54. Velez D., Montoro R., (1998). Arsenic speciation in manufactured seafood products: a review. *J. food. Protect*, 61 (9), 1240-1245.
55. Victor B., Narayanan M., Nelson D. Jones., (1990). Gill pathology and hemocyte response in

- mercury exposed *Macrobrachium idae* (Heller) Journal of Environmental Biology 11(1), 61-5
56. Voegborlo R. B., Methnani A. M. E., Abedin M. Z., (1999). Mercury, cadmium and lead content of canned Tuna fish. Food Chem., 67 (4), 341 – 345.
57. Vogt G., (1994). Life cycle and functional cytology of the hepatopancreatic cells of *Astacus astacus*. Zoomorphology 114, 83-101.
58. Vorkamp K., Christensen J.H, Riget F., (2004). Polybrominated diphenyl ethers and organochlorine compounds in biota from the marine environment of East Greenland. Sci Total Environ. 331:143–55.
59. Vosyliene M. Z., Jankaite A., (2006). Effect of heavy metal model mixture on rainbow trout biological parameters. Ekologija., 4, 12-17.
60. Vutukuru S. S., (2005). Acute effects of Hexavalent chromium on survival, oxygen consumption, hematological parameters and some biochemical profiles of the Indian Major carp, *Labeo rohita*. Int. J. Environ. Res. Public Health., 2 (3), 456- 462.
61. Waqar A., (2006). Levels of selected heavy metals in Tuna fish. Arab. J. Sci. Eng., 31 (1A), 89–92.
62. Weeks-Perkins, B.A., Chansue, N., Wong-Verelle, D. (1995). Assay of immune function in shrimp phagocytes: techniques used as indicators or pesticide exposure. In: Stolen, J.S., Fletcher, T.C., Smith, S.A., Zelikoff, J.T., Kaattari, S.L., Anderson, R.S., Soederha'll, K., Weeks-Perkins, B.A. (Eds.), Techniques in Fish Immunology-4. SOS Publications, Fair Haven, USA, pp. 223–231.
63. White S.L., Rainbow P.S., (1986). Accumulation of cadmium by *Palaemon elegans* (Crustacea: Decapoda). Marine Ecology Progress Series 32: 17-25.
64. World Health Organisation (WHO), (1984). Guidelines for drinking water quality. WHO, Geneva, No.111.
65. Yang Z.B., Zhao Y.L., Li N., Yang J., (2007). Effect of waterborne copper on the microstructure of gill and hepatopancreas in *Eriocheir sinensis* and its induction of metallothionein synthesis. Archives of Environmental Contamination and Toxicology 52: 222-228.
66. Zhao Y., Wang X., Qin Y. , Zheng B., (2010). Mercury (Hg²⁺) effect on enzyme activities and hepatopancreas histostructures of juvenile Chinese mitten crab *Eriocheir sinensis* . Chinese Journal of Oceanology and Limnology Volume 28, (3): 427-434.